

SNUS USERS: INTRAORAL LESIONS, BIOFILM PROPERTIES, COMMUNICATION AND TREATMENT STRATEGIES

Miluna Sintija, Kroica Juta, Pilmane Mara, Skadins Ingus, Koka Rudite, Rostoka Dagnija

Objective: The link between snus, periodontal diseases and oral malignancy is still in question in different literature. This study aims to explore the impact of snus on mucosal lesions and oral malignancy along with evaluation of strategies for snus cessation and approaches to communication with patients.

Methods: A questionnaire about tobacco consumption habits was made. A heavy snus group, a light snus group and a control group were made. Oral biopsy samples were tested for protein gene product 9.5, tissue inhibitor of matrix metalloproteinase 2, chromogranin A and B, matrix metalloproteinase 2, interleukin-1, interleukin-10 using immunohistochemical techniques. Periodontal pocket biofilms were tested with combined polymerase chain reaction and were subsequently analyzed in order to determine the presence of pathogenic periodontal bacteria, such as *Aggregatibacter actinomycetemcomitans*, *Porphyromonas gingivalis*, *Tannerella forsythia*, *Treponema denticola* and *Prevotella intermedia*.

Results: Biopsy results showed cellular disorganization, apoptosis, hyperkeratosis and prevalence of keratotic seborrhea in the area of snus sachets. Microbiological examination revealed the presence of periodontal pathogens in the snus users group. High concentration of pathogenic periodontal bacteria *Aggregatibacter actinomycetemcomitans*, *Porphyromonas gingivalis* and *Prevotella intermedia* was found in groups of both heavy and light snus users, yet they were absent in the samples of the control group. High concentration of *Tannerella forsythia* and *Treponema denticola* was also found in the groups of heavy and light snus users, whereas they were present in samples of only two patients of the control group.

Conclusions: Snus changes cell function, it can lead to oral malignancy and promote periodontal disease regardless of the frequency and amount of snus used.

KEYWORDS: snus, oral malignancy, dental biofilm, periodontal pathogens, addictive patient

INFORMATION ABOUT AUTHORS

Sintija Miluna, DDS, Riga Stradins University, Department of Microbiology and Biology, Dzirciema iela 16, Riga, Latvia, LV 1007, e-mail:sintijamilina@gmail.com, ORCID ID: <https://orcid.org/0000-0002-4002-7270>

Juta Kroica, MD, PhD, Full Prof., Riga Stradins University, Department of Microbiology and Biology, Dzirciema iela 16, Riga, Latvia, LV 1007, e-mail:juta.kroica@rsu.lv, ORCID ID: <https://orcid.org/0000-0003-0805-7063>

Mara Pilmane, MD, PhD, Full Prof., Riga Stradins University, Department of Morphology, Riga, 9 Kronvalda bulvaris, Riga, Latvia, LV 1010, e-mail:mar.pilmane@rsu.lv

Ingus Skadins, MD, PhD, Assoc. Prof., Riga Stradins University, Department of Microbiology and Biology, Dzirciema iela 16, Riga, Latvia, LV 1007, e-mail:ingus.skadins@rsu.lv, ORCID ID: <https://orcid.org/0000-0003-4044-8750>

Rudite Koka, MD, PhD, Assoc. Prof., Riga Stradins University, Department of Microbiology and Biology, Dzirciema iela 16, Riga, Latvia, LV 1007, e-mail:rudite.koka@rsu.lv, ORCID ID: <https://orcid.org/0000-0002-6475-1909>

Dagnija Rostoka, DDS, PhD, Assoc. Prof., Riga Stradins University, Department of Microbiology and Biology, Dzirciema iela 16, Riga, Latvia, Lv 1007, e-mail:dagnija.rostoka@apollo.lv, ORCID ID: <https://orcid.org/0000-0002-8853-6373>

For citation:

Miluna S., Kroica J., Pilmane M., Skadins I., Koka R., Rostoka D. SNUS USERS: INTRAORAL LESIONS, BIOFILM PROPERTIES, COMMUNICATION AND TREATMENT STRATEGIES The Journal of V. N. Karazin Kharkiv National University. Series «Medicine». 2021:43. P. 49–61. DOI: 10.26565/2313-6693-2021-43-06

INTRODUCTION

Smokeless tobacco has become more popular among young adults in Latvia although the sale of snus is prohibited. Young adults are not well-informed about the harm that snus can cause. Moreover, smokeless tobacco is very addictive and harmful for oral

tissue. It induces changes in the oral microbiome and changes properties of the dental biofilm. Some sources claim snus can cause intraoral lesions that can lead to leukoplakia or oral malignancy in areas where sachets have been placed. Smokeless tobacco users place tobacco sachets under the upper or lower lip leading to the development

of white mucosal lesions in these regions exhibiting parakeratosis, leukoedema, cutaneous *lichen simplex chronicus*, leukoplakia-squamous cell hyperplasia [1]. Other oral manifestations include periodontitis, gingivitis, impaired wound healing, pyogenic granuloma, discoloration of teeth, enamel abrasion, etc. [2]. Young adults may not be capable of managing smokeless tobacco cessation on their own, thus snus cessation requires professional treatment and communication.

MATERIALS AND METHODS

An online questionnaire about tobacco consumption strategies were done by 100 respondents. Based on the answers, respondents that used smokeless tobacco were divided in 2 groups: group 1 or light snus users group, n = 13 (1–7 sachets per day) and group 2 or heavy snus users group, n = 15 (more than 7 sachets per day). A control group was made from respondents who do not use tobacco products at all, n = 20.

A questionnaire was followed by an examination of the oral cavity. Oral biopsy was then obtained from the site of lesion from 4 heavy smokeless tobacco users and 3 light smokeless tobacco users.

The biopsy samples were thoroughly washed with normal saline, fixed with formalin and embedded in paraffin. A microtome was used to obtain thin sections (5–7 µm), which were collected on slides and stained with eosin and hematoxylin. Pathological changes were observed using different levels of magnification on a light microscope. Routine staining methods and immunohistochemical techniques for Ki67, protein gene product 9.5 (PGP9.5), tissue inhibitor of matrix metalloproteinase 2 (TIMMP2), chromogranin A and B, matrix metalloproteinase 2 (MMP2), interleukin-1 (IL1), interleukin-10 (IL10) were used on tissue.

Periodontal pocket biofilms from sites of oral lesions were gathered in a sterile Eppendorf test tube for qualitative and

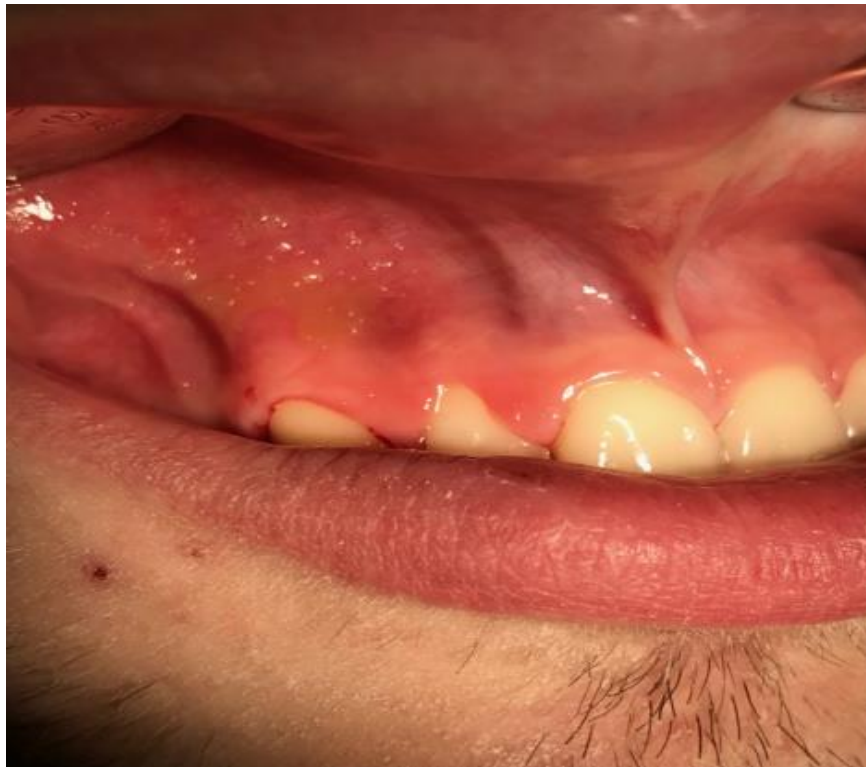quantitative analysis of anaerobic microbiota (n = 7 light smokeless tobacco users or group 1, n = 5 heavy smokeless tobacco users or group 2, n = 10 control group). Bacteria from the samples were identified using combined polymerase chain reaction (PCR Microdent, Hain Lifescience). The volume of bacteria was expressed through the referent interval equivalent/sample. Samples taken from smokeless tobacco users and patients from the control group were analyzed in order to determine the presence of pathogenic periodontal bacteria *Aggregatibacter actinomycetemcomitans* (A.a.), *Porphyromonas gingivalis* (P.g.), *Tannerella forsythia* (T.f.), *Treponema denticola* (T.d.) and *Prevotella intermedia* (P.i.). Statistics SPSS 17.0 was used to analyze differences between the results.

This research was approved by the Ethics Committee of Riga Stradins University, permit № 22/28.01.2016. Written consent was obtained from each patient.

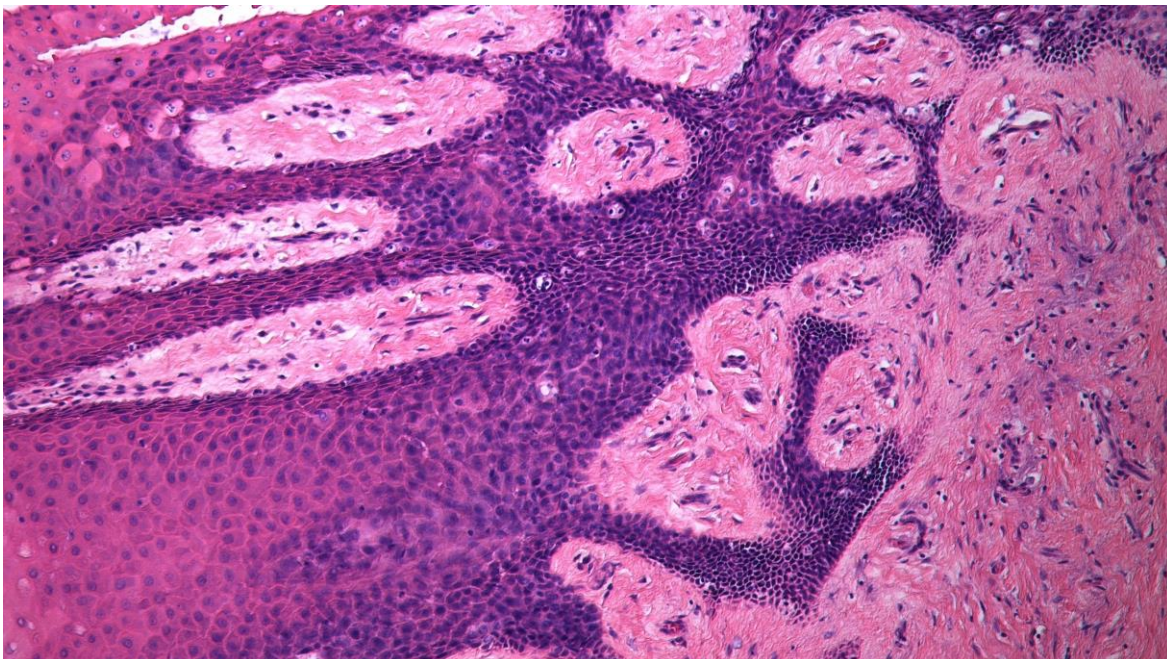
RESULTS

Intraoral examination revealed oral lesions in snus users. The lesions were white, asymptomatic and mostly occurred in regions where snus had been placed. Participants underwent intraoral check-ups to detect mucosal changes and to collect dental biofilm. Mucosal changes were photographed and in case of changes consistent with premalignancy or other indications determined by an oral health specialist, an oral biopsy was taken for further morphological examination of tissue (Figure 1).

Biopsy results showed parakeratosis, basal cell hyperplasia, epithelial disorganization and vacuolization with prevalence of keratotic seborrhea. Oral ulcerations were also demonstrated. Light snus users had inflammation and fibrosis in subepithelial tissue. Heavy snus users had pronounced seborrheic keratosis, cyst-like epithelium degeneration and pyknosis in the core, basal cell hyperplasia in stratified squamous epithelium (Figure 2 and 3).



**Fig. 1. Lesion on the upper jaw above the canine tooth on the right side.
Lesion present in a heavy snus user.**



**Fig. 2. Keratotic seborrhea, epithelial disorganization seen in white lesions
from snus user's oral cavity. Hematoxylin and eosin, magnification 200.**

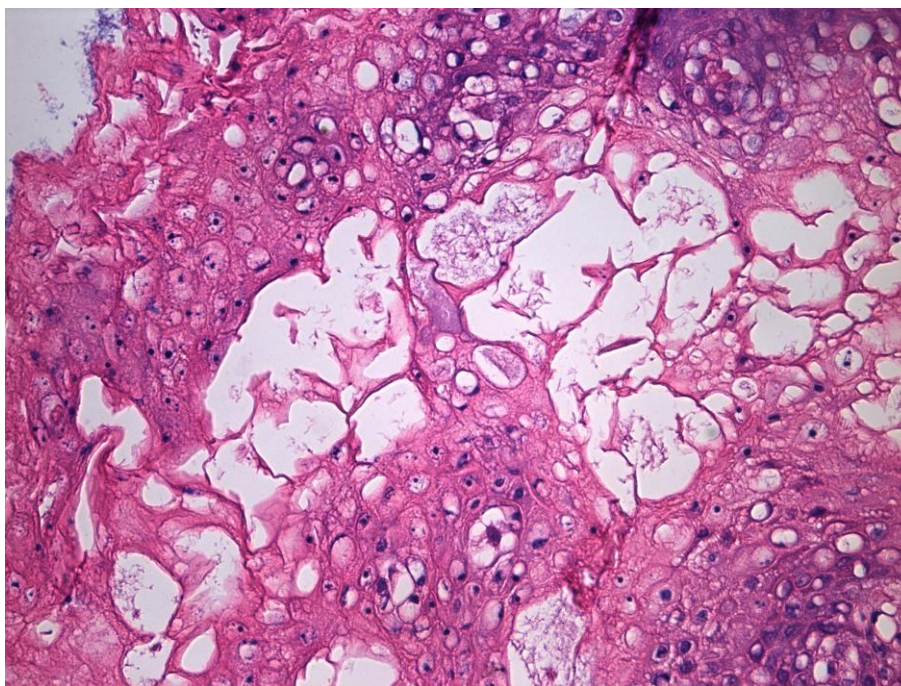


Fig. 3. Keratotic seborrhea, epithelial disorganization seen in white lesions from snus user's oral cavity. Hematoxylin and eosin, magnification 200.

According to histopathological findings, hyperkeratosis was classed as either with or without oral epithelial dysplasia. Oral epithelial dysplasia, generally considered a precancerous lesion, also showed increased cellular proliferation compared with non-dysplastic epithelium. Cell vascularization

indicated seborrheic keratosis that had originated in the basal cell layer. Pyknosis in the core, cell apoptosis related to massive atrophy of epithelial cells, and chronic inflammation with potential of malignant transformation were also found (Figure 4).

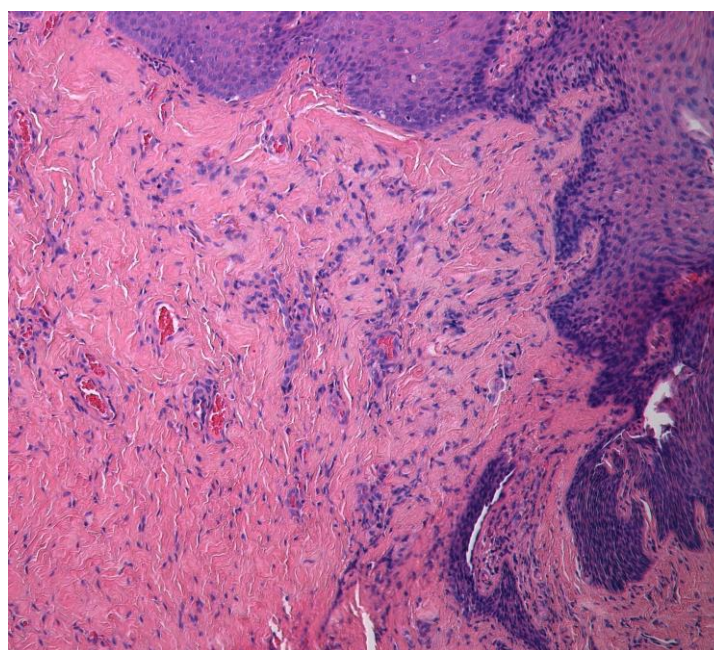


Fig. 4. Oral ulcerations in snus user's oral cavity. Hematoxylin and eosin. Magnification 200.

Oral pathogens were found in all samples collected from light snus users or group 1 (Table 1). Combined polymerase chain reaction was used to determine the concentration of periodontal pathogens. Microbiological examination showed presence of pathogens in all samples collected from heavy snus users (Table 2). Results of quantitative examination revealed varying amounts of pathogens among members of the group 2.

The majority of samples of the control group did not contain pathogenic microorganisms (Table 3). Periodontal pathogenic microorganisms were discovered in three samples of patients in the control group, though in small concentrations, which could be effectively eliminated with the use of local antimicrobial agents. Based on the analysis of the questionnaire, these results can be interpreted as a consequence of insufficient personal oral hygiene. These particular patients did not use dental floss sufficiently or brushed their teeth less than once a day.

Data in table 1 and table 2 shows that both heavy snus users (group 2) and light snus users (group 1) had high concentrations of *A.a.* and no considerable differences existed between heavy and light snus users. All snus users demonstrated a concentration of 10^5 equivalent per sample of *A.a.* obtained from periodontal pocket dental biofilm. Table 3 shows that *A.a.* was not found in the samples of the control group indicating that both light and heavy snus users have unfavorable changes in their microbiome as *A.a.* is the most aggressive periodontal pathogen.

High concentrations (10^6 and 10^7 equivalent per sample) of *P.g.* were found in the heavy and light snus users' groups. *P.g.* was not found in the samples of the control

group. This is a positive microbiological finding as it demonstrates that pathogenic microorganisms such as *P.g.*, associated with chronic periodontal disease, have not spread in the population.

P.i. was found in high concentrations (10^6 and 10^7 equivalent per sample) in the heavy and light snus users' groups. *P.i.* was not found in the samples of the control group. *P.i.* is a periodontal pathogen with a pattern of mixed metabolism (both carbohydrate and protein) that has adapted to existence in biofilms of periodontal pockets and typically causes severe soft tissue damage. Table 3 shows that *P.i.* was not found in the samples of the control group, thus raising hopes that the pathogen is not commonly found in the population.

High concentrations (10^6 and 10^7 equivalent per sample) of *T.f.* were found in the heavy and light snus users' groups. *T.f.* was not found in sample No.9. Small concentrations of *T.f.* were found in samples of the control group (№ 1, № 2, № 3). The results demonstrate that *T.f.* is part of the microbiome of non-users. Therefore, it is likely that the species is more invasive and capable of spreading in the population.

T.d. was found in high concentrations (10^6 and 10^7 equivalent per sample) in the heavy and light snus users' groups. *T.d.* was also found in samples № 1 and № 2 of the control group. The prevalence of this pathogen among snus users is a serious indication of how changes in the microbiome of snus users can contaminate the microbiome of the general population with periodontal pathogens. The long-term consequences of these changes can be linked to various diseases affecting the hard and soft tissue of the oral cavity.

Table 1

Microbiological profiles of light snus users' group (n = 7) (group 1)

Number (No.)	Microorganism				
	<i>A.a.</i>	<i>P.g.</i>	<i>P.i.</i>	<i>T.f.</i>	<i>T.d.</i>
1	+	+++	+++	+++	+++
2	++	+	+++	+++	+++
3	+	+++	++	++	++
4	+	++	+++	+++	+++
5	++	+	+	++	+
6	++	+++	++	+++	+++
7	++	++	++	++	+

(+ = $< 10^5$, exception *A. a.* $< 10^4$ equivalent per sample ; ++ = $< 10^6$ equivalent per sample, exception *A. a.* $< 10^5$ equivalent per sample; +++ = $> 10^7$ equivalent per sample, exception *A. a.* $< 10^6$ equivalent per sample).

Table 2

Microbiological profiles of heavy snus users' group (n = 5) (group 2)

Number (No.)	Microorganism				
	<i>A.a.</i>	<i>P.g.</i>	<i>P.i.</i>	<i>T.f.</i>	<i>T.d.</i>
1	++	++	+++	+++	+
2	++	++	++	++	+
3	++	+++	+++	+++	+++
4	++	+++	++	+++	+++
5	++	++	+++	+++	++

(+ = < 10⁵, exception *A. a.* < 10⁴ equivalent per sample ; ++ = < 10⁶ equivalent per sample, exception *A. a.* < 10⁵ equivalent per sample; +++ = > 10⁷ equivalent per sample, exception *A. a.* < 10⁶ equivalent per sample).

Table 3

Microbiological profiles of control group (n = 10)

Number (No.)	Microorganism				
	<i>A.a.</i>	<i>P.g.</i>	<i>P.i.</i>	<i>T.f.</i>	<i>T.d.</i>
1	negative	negative	negative	+	+
2	negative	negative	negative	+	+
3	negative	negative	negative	++	negative
4	negative	negative	negative	negative	negative
5	negative	negative	negative	negative	negative
6	negative	negative	negative	negative	negative
7	negative	negative	negative	negative	negative
8	negative	negative	negative	negative	negative
9	negative	negative	negative	negative	negative
10	negative	negative	negative	negative	negative

(+ = < 10⁵ equivalent per sample, ++ = < 10⁶ equivalent per sample)

Figure 5 presents the distribution of concentration of bacteria (equivalent/sample) in the group of heavy snus users is more scattered. In the light snus users' group, the concentrations are equally high among the participants (10⁵ equivalent/sample), indicating that the prevalence of *A.a.* is equivalent with the group of heavy users. Based on these data, light usage of snus, i. e. use of less sachets per day, is not linked to reduced risk of infection with *A.a.*

Figure 6 shows the distribution of concentration of bacteria (equivalent/sample) in the heavy snus users' group is more scattered (10⁶–10⁷). Concentration of bacteria in the group of light users is equally high, 10⁷ (equivalent/sample), among the participants. These results show that the prevalence of *P.g.* is equivalent between both groups. Thus, the amount of snus used does not determine the risk of infection with *P.g.*, proving that even infrequent or limited use is dangerous.

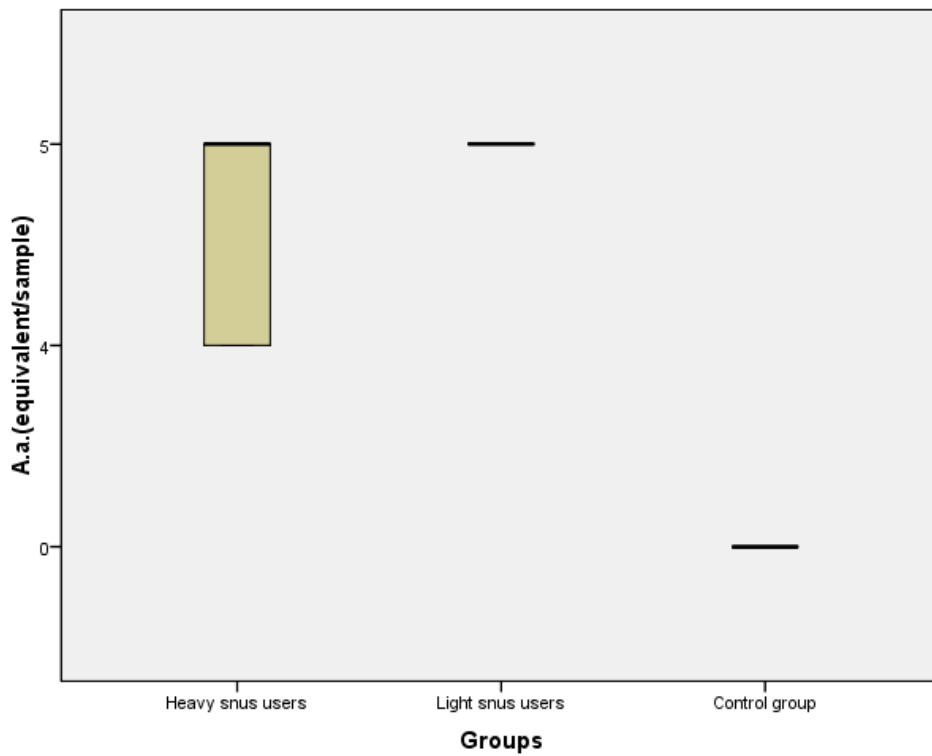


Fig. 5. Distribution of *A.a.* concentrations in heavy snus group, light snus group, control group (equivalent or DNA copy number/sample).

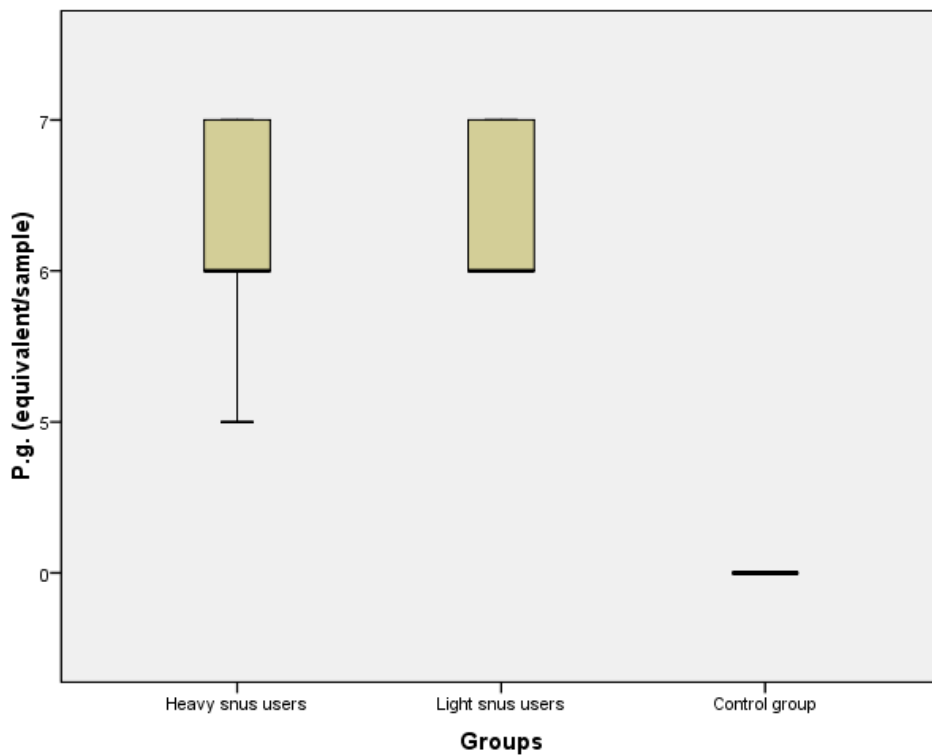


Fig. 6. Distribution of *P.g.* concentrations in heavy snus group, light snus group, control group (equivalent or DNA copy number/sample).

Figure 7. Distribution of concentration of bacteria (equivalent/sample) in the heavy snus users' group is more scattered (10^6 – 10^7). Concentration of bacteria in the group of light users is equally high, 10^7 (equivalent/sample), among the participants. These results show that the prevalence of *P.i.* is equivalent between both groups. Therefore, risk of infection with *P.i.* is equal regardless of the amount of snus used per day.

Figure 8. Data show that *T.f.* has spread to the microbiome of non-users. This pathogen may be more invasive and capable of quicker spread in the population. The average concentration of *T.f.* in samples of the control group was 10^5 . In comparison, the concentration in the group of heavy snus users was from 10^6 to 10^7 equivalent per sample.

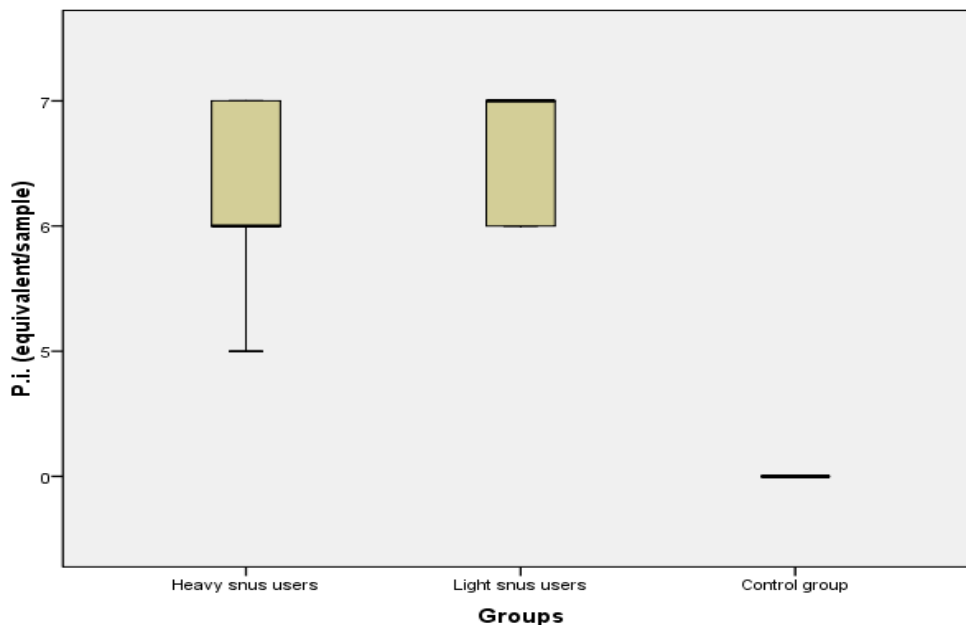


Fig. 7. Distribution of *P.i.* concentrations in heavy snus group, light snus group, control group (equivalent or DNA copy number/sample).

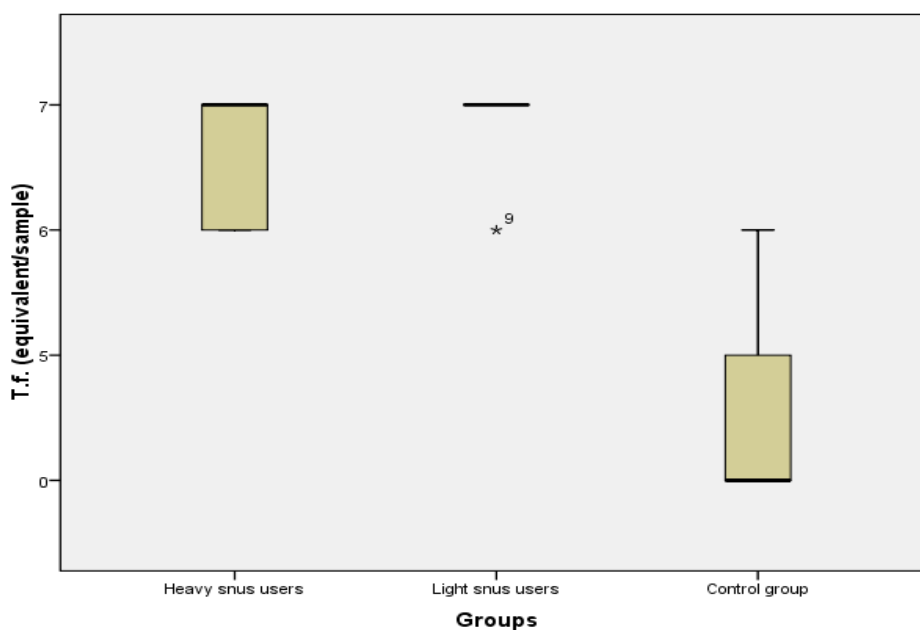


Fig. 8. Distribution of *T.f.* concentrations in heavy snus group, light snus group, control group (equivalent or DNA copy number/sample).

Figure 9. The figure shows an equally high concentration of bacteria in groups of both heavy and light snus users. The concentration in the group of heavy snus

users was from 10^6 to 10^7 equivalent per sample. The pathogen was found in the control group, however at significantly lower concentrations.

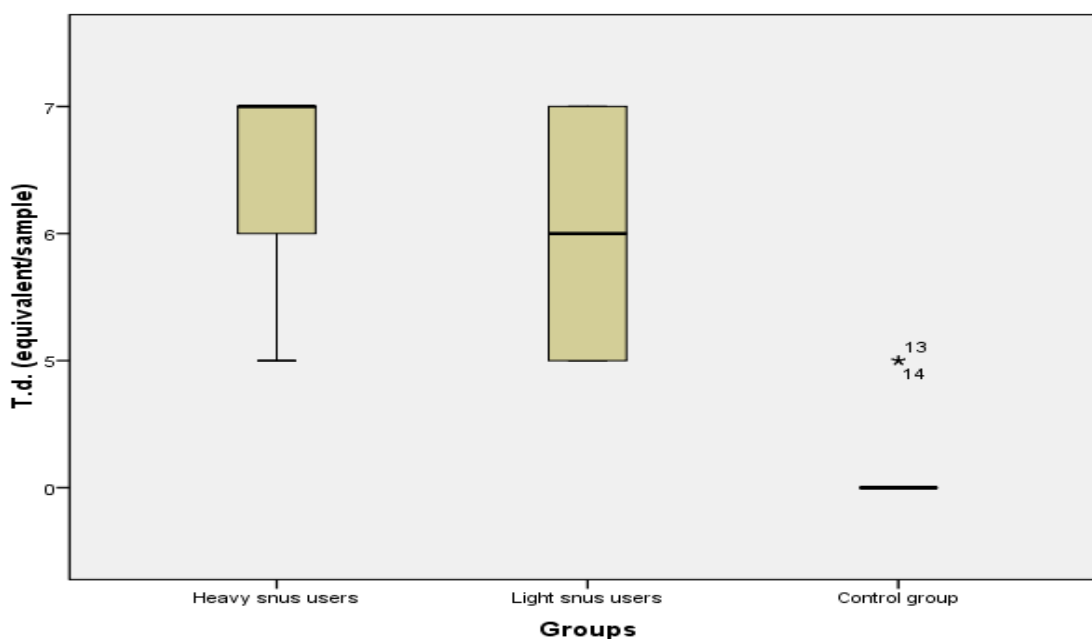


Fig. 9. Distribution of *T.d.* concentrations in heavy snus group, light snus group, control group (equivalent or DNA copy number/sample).

DISCUSSION

The oral cavity, including teeth, the surrounding gingival epithelium, the periodontium, the salivary glands and other structures are open to the oral environment and are exposed to multiple microbiological and pathogenic influences. To prevent persistent inflammation, an efficient defense system is essential to ensure healthy functioning of the oral cavity and other associated organ systems. Keratinocytes are the major constituent of epithelial cells in the skin and in mucosal surfaces such as the oral mucosa. It has been shown that oral keratinocytes play an active role in the adaptive immune response of the oral mucosa [3].

Smokers' melanosis is a focal increase in melanin pigmentation in the oral mucosa found in cigarette, pipe, and cigar smokers who smoke frequently. Melanosis is either a diffuse patch of brownish discolored mucosa or numbers of small solitary melanotic macules. The lesion is not dysplastic or premalignant, however its presence indicates

a continual and frequent smoking habit that places the patient at an increased risk for oral carcinoma. Most lesions are seen on the labial mucosa and floor of the mouth, nevertheless, the tongue, gingiva, and buccal mucosa may also be involved. The lesion is asymptomatic and flat (macular), as if the mucosa was painted a light brown beneath its surface [4].

Although caries and periodontitis are evidently bacterial diseases, they are not infectious diseases in the classical sense as they result from a complex interaction between the commensal microbiota, host susceptibility and environmental factors such as nicotine intake. The human oral microbiome database provides a comprehensive resource consisting of descriptions of oral microbiota [5]. Individuals' oral microbiomes are highly specific at the species level, although overall the human oral microbiome shows few geographical differences. Oral microorganisms adapt to changing environments within protective biofilms [6]. Biofilms are complex colonies of microorganisms, which in the oral cavity are

predominantly found on surfaces of teeth and mucous membranes. While the microbial colonies play vital roles in maintaining oral homeostasis, they also have a significant role in oral diseases [7].

Recent studies have demonstrated that host susceptibility is of primary importance with an as yet uncharacterized defect of the immune system, which impairs the regulation of osteoclast recruitment, differentiation and activation, causing affected individuals to mount an inappropriately aggressively inflammatory response against the normal microbiota [8].

The majority of studies to date investigating the interaction between bacteria and host tissues and immune cells have used single organisms, typically those that have been implicated as pathogens. The host will, however, always be in contact with a highly diverse polymicrobial biofilm and the degree of resulting inflammation will be dependent on a vast number of bacterial-host interactions. Some progress using polymicrobial bacterial challenge has been made, yet new models need to be developed that include a mix of species typical of the natural plaque biofilm [9].

In susceptible individuals, inflammation arises at an early stage of biofilm maturation. It is possible that the gross changes in bacterial composition occur as a result of inflammation rather than causing it. There may be other species, yet to be identified, which play a key role in inducing an inappropriate inflammatory response in the host. Perhaps there are species analogous to *Bifidobacterium* species in the colon that exert an anti-inflammatory effect on oral tissue. Systematic screening should allow assignation of oral bacterial species to specific functional groups based on their interactions with host cells [10].

Tobacco products are a source of numerous toxins [11] that come into direct contact with oral bacteria; these toxins can perturb the microbial ecology of the mouth via antibiotic effects, oxygen deprivation or other potential mechanisms [12]. Loss of beneficial oral species due to smoking can lead to pathogen colonization and ultimately to disease; this contention is strongly supported by the well-established role of smoking in the onset and progression of periodontitis [13]. Testing samples from the

mouth can show how microbiota is related to health and disease. However, the microbiota in a person's mouth differs depending on the methods of collection and the part of the mouth that is tested. Understanding what can change the microbiota of smokers and snus users will give more information on how to study oral microbiota, smoking-related cancers and other diseases.

It has been proven that nicotine is addictive and it compares to drugs such as heroin or cocaine. Nicotine increases the level of epinephrine stimulating the body and mind, increasing blood pressure, heart rate and respiration. Nicotine also stimulates dopamine release evoking the feeling of pleasure [14].

For preventive purposes, all tobacco products should be removed from the patient's household. A few hours after quitting tobacco products a patient can have withdrawal symptoms, such as headaches, coughing, cravings, increased appetite, mood changes, restlessness, decreased heart rate and others. These symptoms are temporary, however there are possibilities to deal with them. Cognitive-behavioral therapy is known to reduce withdrawal symptoms. Regular sports activities also reduce desire for tobacco and stress [15]. Hypnotherapy and acupuncture can also be considered as potential treatment for symptoms of withdrawal [16].

Some studies show that assisted self-care tobacco cessation programs are effective [17]. Setting a date for quitting helps in the process of quitting tobacco products and yields better results [18]. Latest studies show that in the case of young adults, the best tobacco cessation programs involve the use of mobile apps or Internet programs. Benefits of online apps are accessibility and motivation alerts. Although mobile apps are effective among young adults, their use is not suitable for elderly individuals [19]. Some other effective cessation programs for adults are group-counseling sessions, self-help materials and counseling by phone. Nicotine replacement therapy has shown lower cessation rates than varenicline therapy [20].

Government plays a big role in tobacco cessation. Some countries have developed smoke-free environments, for example, Sweden, good cessation programs, and high taxes. In addition, mass media and pack

warnings are important in tobacco cessation and effective communication with tobacco users [21].

Children are influenced by both their family members and classmates at school. There is evidence that children that had been bullied at school have a tendency to start using tobacco products more often than children who were not bullied [22].

CONCLUSIONS

- Snus changes cell function and can lead to development of oral malignancy.

- Snus promotes periodontal diseases regardless of frequency and amount of snus used.
- Oral professionals should inform snus users about potential risks and harm.
- More information should be provided to young adults about the harm of snus use.
- Professionals should utilize psychotherapy and pharmacological therapy for treatment of snus users.
- Further studies on oral microbiome should be carried out in order to evaluate changes to the oral cavity and their causes in early snus users.

REFERENCES

1. Müller S. Frictional Keratosis, Contact Keratosis and Smokeless Tobacco Keratosis: Features of Reactive White Lesions of the Oral Mucosa. *Head Neck Pathol.* 2019 Mar; 13 (1): 16–24. Doi: <https://doi.org/10.1007/s12105-018-0986-3>. Epub 2019 Jan 22. PMID: 30671762; PMCID: PMC6405791.
2. Greer RO Jr. Oral manifestations of smokeless tobacco use. *Otolaryngol Clin North Am.* 2011 Feb; 44 (1): 31–56, v. Doi: <https://doi.org/10.1016/j.otc.2010.09.002>. PMID: 21093622.
3. Pivarsci A, Kemény L, Dobozy A. Innate immune functions of the keratinocytes. A review. *Acta Microbiol Immunol Hung.* 2004; 51 (3): 303–10. Doi: <https://doi.org/10.1556/AMicr.51.2004.3.8>. PMID: 15571070.
4. Khan Z, Albuquerque R, Richards A. Malignant oral melanoma: how to spot it and how it is managed. *Dental Update.* 2018; 45 (7): 660–664. Doi: <https://doi.org/10.12968/denu.2018.45.7.660>.
5. Expanded Human Oral Microbiome Database. [Internet]. 2018 August 16. Available from: <http://www.homd.org>.
6. Sultan AS, Kong EF, Rizk AM et al. The oral microbiome: A Lesson in coexistence. *PLUS pathogens.* 2018; 14 (1): e1006719.
7. Flemmig TF, Beikler T. Control of oral biofilms. *Periodontol 2000.* 2011; 55: 9–15.
8. Taubman M, Kawai T, Han X. The new concept of periodontal disease pathogenesis requires new and novel therapeutic strategies. *Journal of Clinical Periodontology.* 2007; 34, 367–369.
9. Huang CB, Altimova Y, Strange S, et al. Polybacterial challenge effects on cytokine/chemokine production by macrophages and dendritic cells. *Inflammation Research,* 2010. Doi: <https://doi.org/10.1007/500011-010-0242-0>.
10. Preising J, Philippe D, Gleinser M, et al. Selection of bifidobacteria based on adhesion and anti-inflammatory capacity in vitro for amelioration of murine colitis. *Applied and Environmental Microbiology.* 2010; 76: 3048–3051.
11. WHO. IARC Monographs on the Evaluation of Carcinogenic Risks to Humans. IARC Monographs vol. 100. 2012.
12. Macgregor ID. Effects of smoking on oral ecology. A review of the literature. *ClinPrev Dent.* 1989; 11: 3–7.
13. Nociti FH, Casati MZ, Duarte PM. Current perspective of the impact of smoking on the progression and treatment of periodontitis. *Periodontology 2000.* 2015; 67: 187–210.
14. Henningfield JE, Cohen C, Slade JD. Is nicotine more addictive than cocaine? *British Journal of Addiction.* 1991; 86: 565–569.
15. Kendall-Tackett K. Treatments for depression that lower inflammation: Additional support for an inflammatory etiology of depression. *The Psychoneuroimmunology of Chronic Disease: Exploring the links between Inflammation, Stress, and Illness.* 1st ed. Washington DC: American Psychological Association. 2010; 243–247.
16. Haddad A, Davis AM. Tobacco smoking cessation in Adults and Pregnant Women behavioral and pharmacotherapy interventions. *JAMA Clinical guidelines Synopsis.* 2015; 315 (18).
17. Hatsukami DK, Severson HH. Oral spit tobacco: Addiction, prevention and treatment. *Nicotine & Tobacco Research.* 1999; 1, 21–44.
18. Fiore MC, Bailey WC, Cohen SJ et al. Treating tobacco use and dependence. Clinical practice guideline. Rockville, MD: U.S. Department of Health and Human Services. Public Health Service. 2000.

19. Pulverman R, Yellowlees PM. Smart Devices and a Future of Hybrid Tobacco Cessation Programs. *Telemedicine Journal And E-Health: The Official Journal Of The American Telemedicine Association*. 20 (3)
20. Haddad A, Davis AM. Tobacco smoking cessation in Adults and Pregnant Women behavioral and pharmacotherapy interventions. *JAMA Clinical guidelines Synopsis*, 2015; 315 (18).
21. WHO report on the global tobacco epidemic. Raising taxes on tobacco. Executive summary. [Internet]. 2015. Available from: http://apps.who.int/iris/bitstream/10665/178577/1/WHO_NMH_PND_15.5_eng.pdf?ua=1&ua=1
22. Case KR, Cooper M, Creamer M, Mantey D, Kelder S. Victims of Bullying and Tobacco Use Behaviors in Adolescents: Differences Between Bullied at School, Electronically, or Both. *J Sch Health*. 2016 Nov; 86 (11): 832–840. Doi: <https://doi.org/10.1111/josh.12437>. PMID: 27714875.

СПОЖИВАЧІ СНЮСУ: УРАЖЕННЯ СЛИЗОВОЇ ОБОЛОНКИ РОТА, ВЛАСТИВОСТІ БІОПЛІВКИ, КОМУНІКАЦІЯ ТА СТРАТЕГІЇ ЛІКУВАННЯ

Сінтія Мілюна, Юта Кройча, Мара Пілманс, Інгус Скадінш, Рудіте Кока, Дагнія Ростока

Метою роботи є визначення мікробіологічних особливостей біоплівки верхніх та нижніх ясен у споживачів бездимного тютюну та порівняння отриманих результатів з аналогічними результатами, отриманими при обстеженні пацієнтів, які ніколи не вживали тютюнові продукти.

Матеріал та методи. Для кількісного та якісного дослідження анаеробної мікрофлори у стерильній пробірці Епендорф збиралися біоплівки періодонтальних кишень у районі верхніх та нижніх ясен. Патогенні періодонтальні бактерії в біоплівці визначалися полімеразної ланцюгової реакції. Для споживачів бездимного тютюну – пацієнтів контрольної групи були визначені *Aggregatibacter actinomycetemcomitans*, *Porphyromonas gingivalis*, *Tannerella forsythia*, *Treponema denticola*, *Prevotella intermedia* – кількість (у чисельному вираженні) періодонтальних патогенів у зразках біоплівки верхніх та нижніх. Для проведення дослідження було одержано дозвіл Комітету з етики РСУ № NR.22 від 28.01.2016.

Результати. Патогенні бактерії, що є в популяції, циркулюють від людини, хворої на періодонтит, потрапляючи в мікробіом ротової порожнини здорової людини.

Висновки. Результати користувачів бездимного тютюну перевищують допустимі межі, що збільшує ризик розвитку в майбутньому періодонтиту та інших хвороб. У матеріалах біоплівки пацієнтів, які не вживають бездимний тютюн, не виявляється наявності патогенних мікроорганізмів *A. actinomycetemcomitans*. У слині та біоплівках споживачів бездимного тютюну зустрічаються *T.forsythensis*, *T.denticola*, *A. actinomycetemcomitans*, які є патогенними періодонтальними мікроорганізмами. Для споживачів бездимного тютюну існує висока ймовірність не тільки захворіти на періодонтит, а й набути залежність, яка змінює мікрофлору рота, а надалі може негативно вплинути на загальний стан здоров'я.

КЛЮЧОВІ СЛОВА: снус, злоякісні пухлини порожнини рота, зубна біоплівка, пародонтоз, хворий з залежністю

ИНФОРМАЦІЯ ПРО АВТОРІВ

Сінтія Мілюна, докторант, Рижский Университет Страдиня, Кафедра мікробіології та біології, ул. Дзірцієма, 16, Рига, Латвія, LV 1007, e-mail: sintijamiluna@gmail.com, ORCID ID: <https://orcid.org/0000-0002-4002-7270>

Юта Кройча, д.мед.н., професор, Рижский Университет Страдиня, Кафедра мікробіології та біології, вул. Дзірцієма, 16, Рига, Латвія, LV 1007, e-mail: juta.kroica@rsu.lv, ORCID ID: <https://orcid.org/0000-0003-0805-7063>

Мара Пілманс, д.мед.н., професор, Рижский Университет Страдиня, Інститут анатомії та морфології, б. Кронвалда, 9, Рига, Латвія, LV 1010, e-mail: mara.pilmane@rsu.lv

Інгус Скадінш, д.мед.н., професор, Рижский Университет Страдиня, Кафедра мікробіології та біології, вул. Дзірцієма, 16, Рига, Латвія, LV 1007, e-mail: ingus.skadins@rsu.lv, ORCID ID: <https://orcid.org/0000-0003-4044-8750>

Рудіте Кока, д.мед.н., професор, Рижский Университет Страдиня, Кафедра мікробіології та біології, вул. Дзірцієма, 16, Рига, Латвія, LV 1007, e-mail: rudite.koka@rsu.lv, ORCID ID: <https://orcid.org/0000-0002-6475-1909>

Дагнія Ростока, д.мед.н., професор, Рижский Университет Страдиня, Кафедра мікробіології та біології, вул. Дзірцієма, 16, Рига, Латвія, LV 1007, e-mail: dagnija.rostoka@apollo.lv, ORCID ID: <https://orcid.org/0000-0002-8853-6373>

Для цитування:

Мілюна С., Кройча Ю., Пилмане М., Скадиньш І., Кока Р., Ростока Д. СПОЖИВАЧІ СНЮСУ: УРАЖЕННЯ СЛИЗОВОЇ ОБОЛОНКИ РОТА, ВЛАСТИВОСТІ БІОПЛІВКИ, КОМУНІКАЦІЯ ТА СТРАТЕГІЇ ЛІКУВАННЯ. Вісник Харківського національного університету імені В. Н. Каразіна. Серія «Медицина». 2021:43; С. 49–61. DOI: 10.26565/2313-6693-2021-43-06

ПОТРЕБИТЕЛИ СНЮСА: ПОРАЖЕННЯ СЛИЗИСТОЙ ОБОЛОЧКИ РТА, СВОЙСТВА БІОПЛЕНКИ, КОМУНІКАЦІЯ І СТРАТЕГІЇ ЛІЧЕННЯ

Мілюна С., Кройча Ю., Пилмане М., Скадиньш І., Кока Р., Ростока Д.

Цель работы. Целью работы является определение микробиологических особенностей биопленки верхних и нижних десен у потребителей бездымного табака, и сравнение полученных результатов с аналогичными результатами, полученными при обследовании пациентов, которые никогда не употребляли табачные продукты.

Материал и методы. Для количественного и качественного исследования анаэробной микрофлоры в стерильной пробирке Эпендорф собирались биопленки периодонтальных карманов в районе верхних и нижних десен. Патогенные периодонтальные бактерии в биопленке определялись полимеразной цепной реакцией. Для потребителей бездымного табака – пациентов контрольной группы были определены *Aggregatibacter actinomycetemcomitans*, *Porphyromonas gingivalis*, *Tannerella forsythia*, *Treponema denticola*, *Prevotella intermedia* – количество (в численном выражении) периодонтальных патогенов в образцах биопленки верхних и нижних десен. Для проведения исследования было получено разрешение Комитета по этике РСУ № NR.22 от 28.01.2016.

Результаты. Патогенные бактерии, имеющиеся в популяции, циркулируют от человека, больного периодонтитом, попадая в микробиом ротовой полости здорового человека.

Выводы. Результаты пользователей бездымного табака превышают допустимые границы, что увеличивает риск развития в будущем периодонтита и других болезней. В материалах биопленки пациентов, не употребляющих бездымный табак, не обнаруживается наличие патогенных микроорганизмов *A. actinomycetemcomitans*. В слюне и биопленках потребителей бездымного табака встречаются *T.forsythensis*, *T.denticola*, *A. actinomycetemcomitans*, которые являются патогенными периодонтальными микроорганизмами. Для потребителей бездымного табака существует высокая вероятность не только заболеть периодонтитом, но и приобрести зависимость, которая меняет микрофлору рта, а в дальнейшем может негативно повлиять на общее состояние здоровья.

КЛЮЧЕВЫЕ СЛОВА: снус, злокачественные опухоли полости рта, зубная биопленка, пародонтоз, больной с зависимостью

ИНФОРМАЦИЯ ОБ АВТОРАХ

Синтия Милуна, докторант, Рижский Университет Страдиня, Кафедра микробиологии и биологии, ул. Дзирциема, 16, Рига, Латвия, LV 1007, e-mail: sintijamiluna@gmail.com, ORCID ID: <https://orcid.org/0000-0002-4002-7270>

Юта Кройча, д.мед.н., профессор, Рижский Университет Страдиня, Кафедра микробиологии и биологии, ул. Дзирциема, 16, Рига, Латвия, LV 1007, e-mail: juta.kroica@rsu.lv, ORCID ID: <https://orcid.org/0000-0003-0805-7063>

Мара Пилмане, д.мед.н., профессор, Рижский Университет Страдиня, Институт анатомии и морфологии, б. Кронвалда 9, Рига, Латвия, LV 1010, e-mail: mara.pilmane@rsu.lv

Ингус Скадиньш, д.мед.н., профессор, Рижский Университет Страдиня, Кафедра микробиологии и биологии, ул. Дзирциема, 16, Рига, Латвия, LV 1007, e-mail: ingus.skadins@rsu.lv, ORCID ID: <https://orcid.org/0000-0003-4044-8750>

Рудите Кока, д.мед.н., профессор, Рижский Университет Страдиня, Кафедра микробиологии и биологии, ул. Дзирциема, 16, Рига, Латвия, LV 1007, e-mail: rudite.koka@rsu.lv, ORCID ID: <https://orcid.org/0000-0002-6475-1909>

Дагния Ростока, д.мед.н., профессор, Рижский Университет Страдиня, Кафедра микробиологии и биологии, ул. Дзирциема, 16, Рига, Латвия, LV 1007, e-mail: dagnija.rostoka@apollo.lv, ORCID ID: <https://orcid.org/0000-0002-8853-6373>

Conflicts of interest: author has no conflict of interest to declare.

Конфлікт інтересів: відсутній.

Конфликт интересов: отсутствует.

Отримано: 08.09.2021 року

Прийнято до друку: 09.11.2021 року

Received: 08.09.2021

Accepted: 09.11.2021