

UDC: 616.127-005.8

CLINICAL CASE OF PATIENT WITH MYOCARDIAL «BRIDGE» OR WHAT CAN BE HIDDEN BEHIND A TYPICAL CLINIC OF ANGINA PECTORIS

Shmidt E. Y.^{1,2}, Prylutcka K. Y.^{1,2}, Medvid E. P.²

¹ V. N. Karazin Kharkiv National University, Kharkiv, Ukraine

² Kharkiv Railway Clinical Hospital № 1 of Branch «Health Center» of the Public joint stock company «Ukrainian Railway», Kharkiv, Ukraine

The article presents a clinical case, when the myocardial bridge was manifested with symptoms typical for angina pectoris. It is also emphasized the importance of carrying out of coronary angiography for such patients, and the effectiveness of stenting in cases of hemodynamically significant muscle bridges is noted.

KEY WORDS: myocardial «bridging», tunneled artery, angiography, ischemic disease, angina pectoris, atherosclerosis, anomalies of coronary vessels

КЛІНІЧНИЙ ВИПАДОК ПАЦІЄНТА З МІОКАРДІАЛЬНИМ МОСТИКОМ, АБО ЩО МОЖЕ ПРИХОВУВАТИСЯ ЗА КЛІНІКОЮ ТИПОВОЇ СТЕНОКАРДІЇ

Шмідт О. Ю.^{1,2}, Прилуцька К. Ю.^{1,2}, Медвідь О. П.²

¹ Харківський національний університет імені В. Н. Каразіна, м. Харків, Україна

² Харківська клінічна лікарня на залізничному транспорті № 1. Філія «Центр охорони здоров'я» публічного акціонерного товариства «Українська залізниця», м. Харків, Україна

У статті розглядається клінічний випадок, коли міокардіальний місток маніфестував симптомами, що типові для стенокардії. Також підкреслюється важливість проведення у таких пацієнтів коронарографії, та зауважується ефективність у випадках гемодинамічно значущих міокардіальних містках.

КЛЮЧОВІ СЛОВА: міокардіальний місток, тунельна артерія, ангиографія, ішемічна хвороба, стенокардія, атеросклероз

КЛИНИЧЕСКИЙ СЛУЧАЙ ПАЦИЕНТА С МИОКАРДИАЛЬНЫМ МОСТИКОМ ИЛИ ЧТО МОЖЕТ СКРЫВАТЬСЯ ЗА КЛИНИКОЙ ТИПИЧНОЙ СТЕНОКАРДИИ

Шмидт Е. Ю.^{1,2}, Прилуцкая Е. Ю.^{1,2}, Медведь Е. П.²

¹ Харьковский национальный университет имени В. Н. Каразина, г. Харьков, Украина

² Харьковская клиническая больница на железнодорожном транспорте № 1. Филиала «Центр здравоохранения» Публичного акционерного общества «Украинская железная дорога», г. Харьков, Украина

В статье представлен клинический случай, когда мышечный мостик манифестировал симптомами, типичными для стенокардии. Также подчеркивается важность проведения у таких пациентов коронарографии и отмечается эффективность стентирования в случаях гемодинамически значимых мышечных мостиков.

КЛЮЧЕВЫЕ СЛОВА: миокардиальный мостик, туннельная артерия, ангиография, ишемическая болезнь, стенокардия, атеросклероз

INTRODUCTION

The myocardial «bridge» at first was recognized at autopsy by Reyman in 1737 and

first described angiographically by Portmann and Iwig in 1960 [1–3].

In 1995, R. Stables conducted the first stenting of the tunneled segment. Myocardial bridging is a congenital anomaly in which a

segment of a coronary artery takes a «tunneled» intramural course under a «bridge» of overlying myocardium [4]. The true frequency of MB is unknown. Numerous authors give a variety data – from 5 to 87 % [5].

There are reasons to think that the myocardial «bridges» are present in almost a one third of adults [5].

Hemodynamically significant myocardial «bridges» during coronary angiography are found in 0.5–4.9 % of patients [5–6].

The MB is usually described for the left anterior descending artery, and besides the middle segment of the LDA being considered as the most common location, but other large coronary arteries may also be involved in the process. Myocardial bridging does not produce any symptoms in the majority of patients. However, deeper bridging (> 2 mm) or MB with significant compression can manifest with myocardial ischemia, acute coronary syndromes, coronary spasm, exercise-induced dysrhythmias (such as supraventricular tachycardia, ventricular tachycardia, or atrioventricular block), myocardial stunning, transient ventricular dysfunction, syncope, sudden death [6].

Coronary angiography remains the most common technique for MB diagnostic [6–7].

It gives complete information about the anatomy of the coronary arteries, the localization of MB and about the degree of narrowing of the CA in systole and in diastole. Asymptomatic patients with MB do not need treatment. In patients with symptoms, medicines such as beta-blockers and calcium channel blockers are usually the first line of treatment. But in refractory to medication cases or in cases with significant systolic compression of coronary artery (more than 70 %) stent implantation can be one of the method for surgery management of MB. The purpose of our work is to present a clinical case when MB induced the symptoms of angina pectoris and to emphasize the importance of coronary angiography and stent implantation in diagnostic and treatment of symptomatic MB.

OUR CASE

Patient: female, 67 years old.

Complaints: was admitted to the cardiologycal department with complaints of pressing retrosternal pain, connected and without connection with physical exertion,

relieved at rest. These complaints had noted first about six months ago.

History of the disease: patient has been suffering from hypertension since 1989, the maximum level of BP was 210/100 mm Hg. Because of hypertension periodically she was hospitalized in the cardiologycal department. She regularly takes medicine: equator 20/10 mg, bisoprolol 5 mg, roxera 20 mg.

Objective examination: active position, skin and visible mucous without changes. Above the lungs: by percussion clear pulmonary (resonant) sound, by auscultation – vesicular breathing. Auscultation of the heart – rhythmic heart sounds, accentuated II tone over the aorta. Pulse – 61 beats per minute, BP – 140/80 mm Hg. The abdomen is soft, painless, the liver is at the edge of the costal arch. Pasternatsky syndrome is negative at both sides. There are no signs of peripheral edema.

Preliminary diagnosis: Hypertension II stage 3 degree, hypertensive heart. HF 0-I. Moderate additional risk IHD. The diagnosis of stable angina was on discussion. To clarify the diagnosis of stable angina, in addition to the standard plan of investigation for patients with hypertension, a treadmill test was prescribed.

RESULTS OF THE SURVEY

General blood and urinary tests: didn't show significant pathological changes.

Biochemical blood tests: total bilirubin – 7.76 $\mu\text{mol/l}$, ALT 29 U/L, creatinine – 93.95 $\mu\text{mol/l}$, glucose 6.64 $\mu\text{mol/l}$. Lipid spectrum: triglycerides 3.3 mmol/l, total cholesterol – 7.93 mmol/l, HDL – 1.43 mmol/l, LDL – 0.77 mmol/l, atherogenic coefficient – 5.4. The conclusion is: mild hyperlipidemia.

ECG: sinus rhythm with heart rate 81 beats/min. ECG signs of left ventricle hypertrophy (Fig. 1).

ECHO-CG: diameter of aorta – 32mm (20–37 mm), mitral valve opening – 29mm (26–35 mm), left atrium – 32 mm, left ventricle end diastolic diameter – 40 mm (35–55), end systolic diameter – 25 mm (23–38 mm), ejection fraction – 65 % (55–78 %), systolic fraction 34 % (28–44 %), interventricular septum – 11.8 mm (6–11 mm), right atrium – 28 mm, right ventricle – 18 mm (9–26), thickness of LV posterior wall – 12.7 mm (6–11 mm). Conclusion: there are atherosclerotic changes of the aorta, hypertrophy of the left ventricle. EKG-monitoring + BP-monitoring: the heart rate corresponds to age norm. During

24 hours submaximal heart rate was not achieved (63 % of the maximum possible for patient's age). Ventricular and atrial ectopic

activity was not revealed. Levels of systolic and diastolic blood pressure are corresponded for mild hypertension.

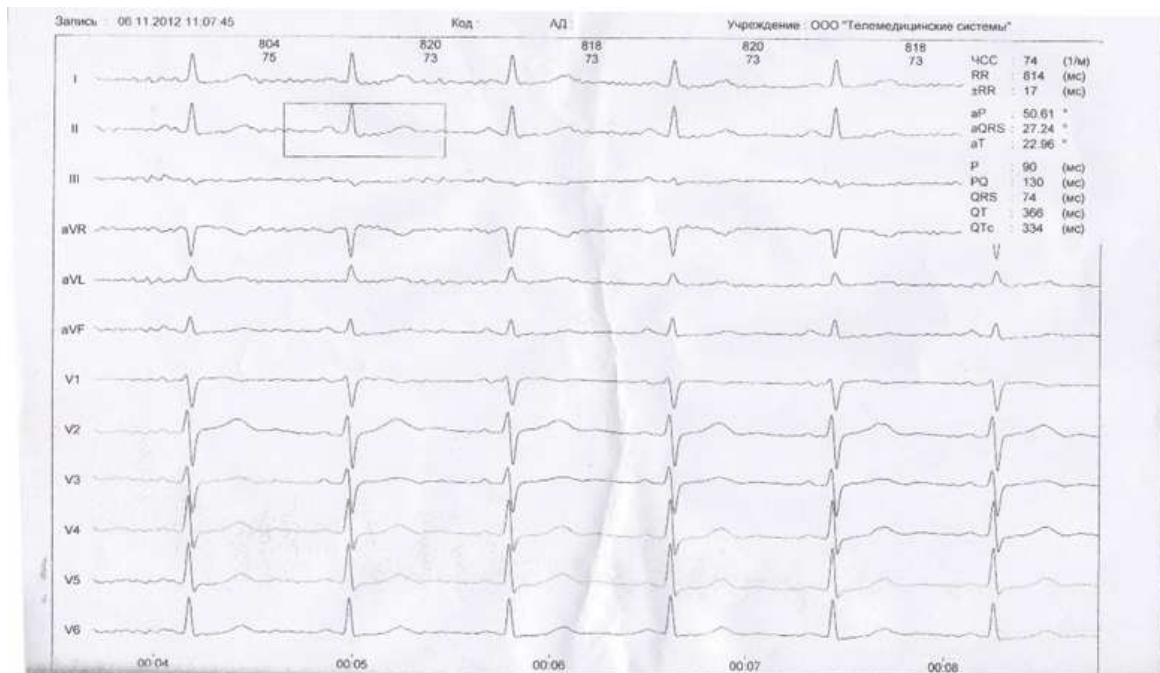


Fig. 1. ECG

Treadmill test: while doing exercise treadmill test (by Bruce protocol) blood pressure, heart rate and 12-leads ECG were recorded during several steps with increased physical exertions (from 4,6 METs) (Fig. 2). The ECG and ST-segment were continuously displayed and measured automatically by a computer-assisted system in all 12 leads. Max reached BP was 180/100 mm Hg, max HR 127

bpm. At heart rate of 120 beats per minute (7,0 METs), the ST segment showed progressive depression more than 1,0 mm in leads II, III, aVF, V4, V5, V6 that necessitated termination of the test (Fig. 3). The patient complained only on mild dyspnea and tiredness. During 4 minutes of restitution period there was complete recovery of ST-segment. Conclusion: test is positive.

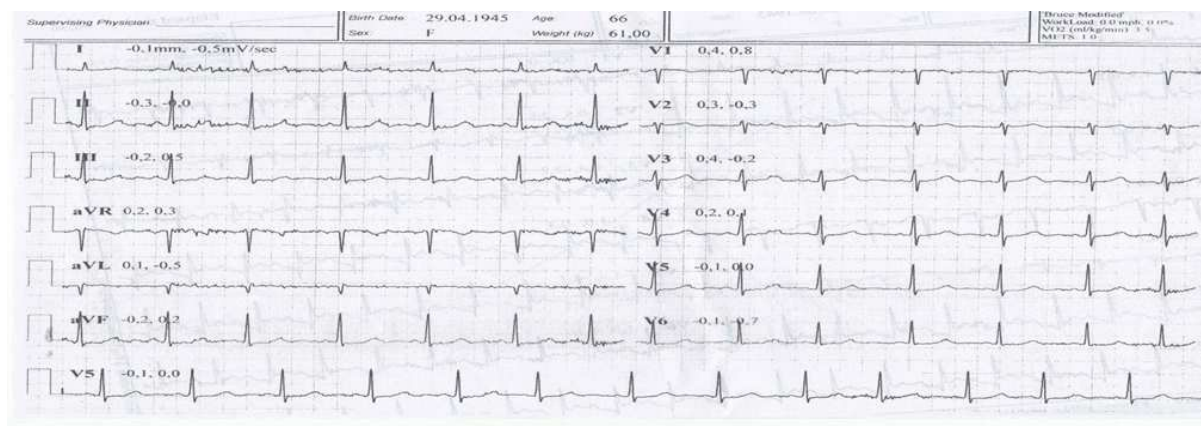


Fig. 2. (Early stage 4,6 METs)

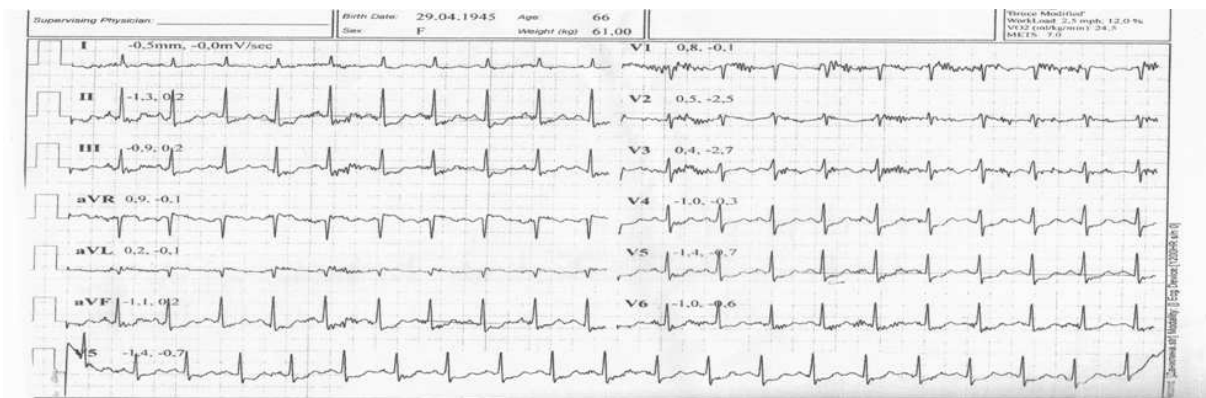


Fig. 3. (The 3-d minutes of 7,0 METs (ST depression))

Taking into account the positive treadmill test, retrosternal pain, coronary angiography was recommended to clarify coronary arteries condition and to decide about further tactic of the patient's management. Indication class-1.

Coronary angiography conclusion: the right type of coronary blood supply. Significant coronary tortuosity. Left coronary artery – prolonged myocardium bridging in the middle

segment of the left anterior descending coronary artery (LAD) with systolic compression 90 % (Fig. 4A, 4B). The circumflex artery branches of the left coronary artery and right coronary artery have signs of atherosclerotic lesions without hemodynamic significance. Direct stenting with DES resolute integrity stent 3.0×38 mm was performed (Fig. 4C, Fig. 5).

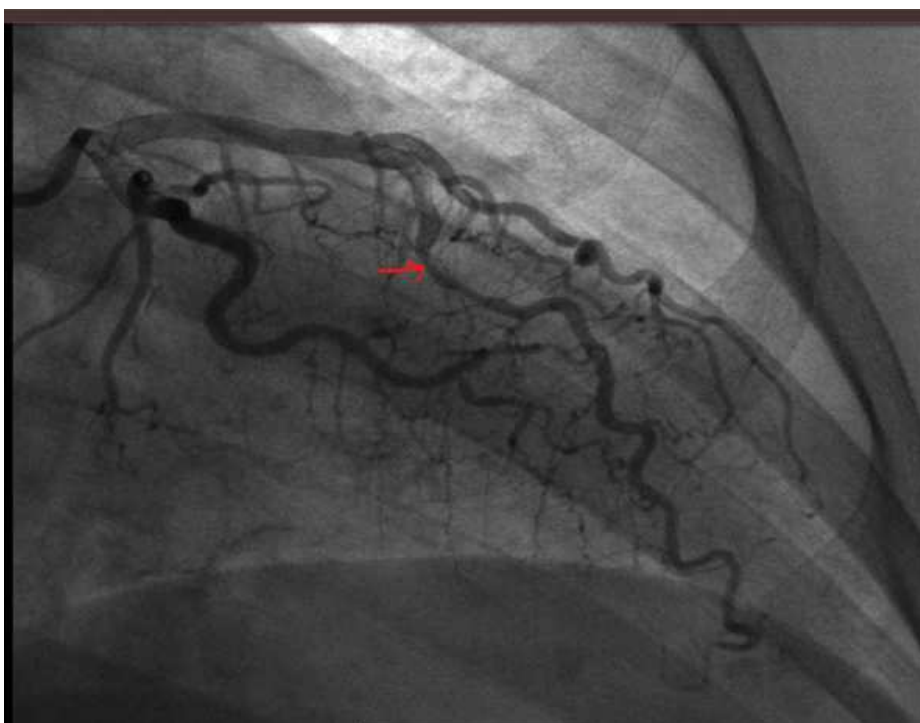


Fig. 4A. Compression of the average segment of the LAD into systole

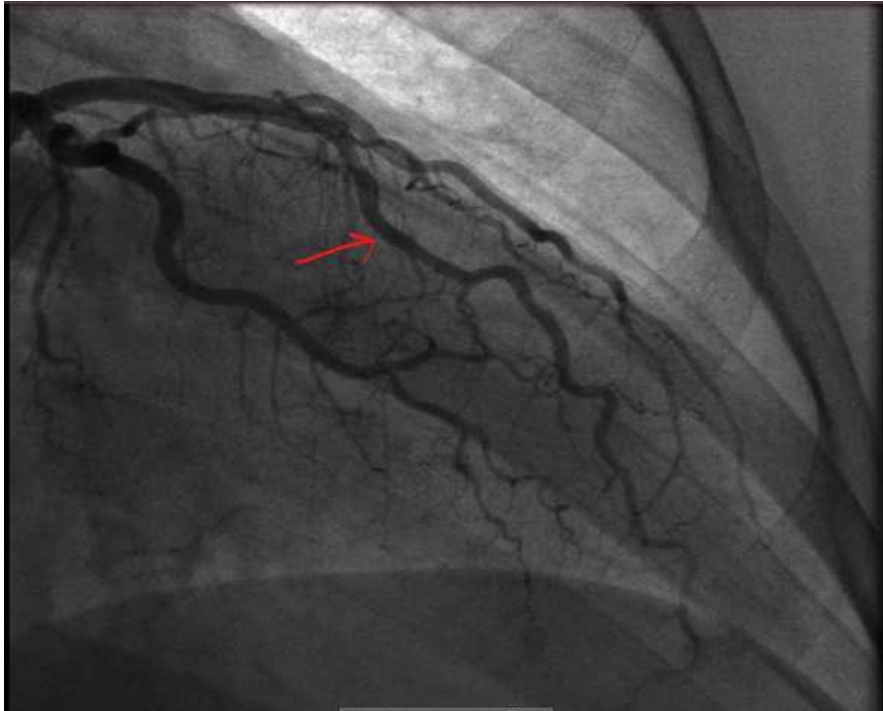


Fig. 4B. Condition of the average segment of the LAD in diastole

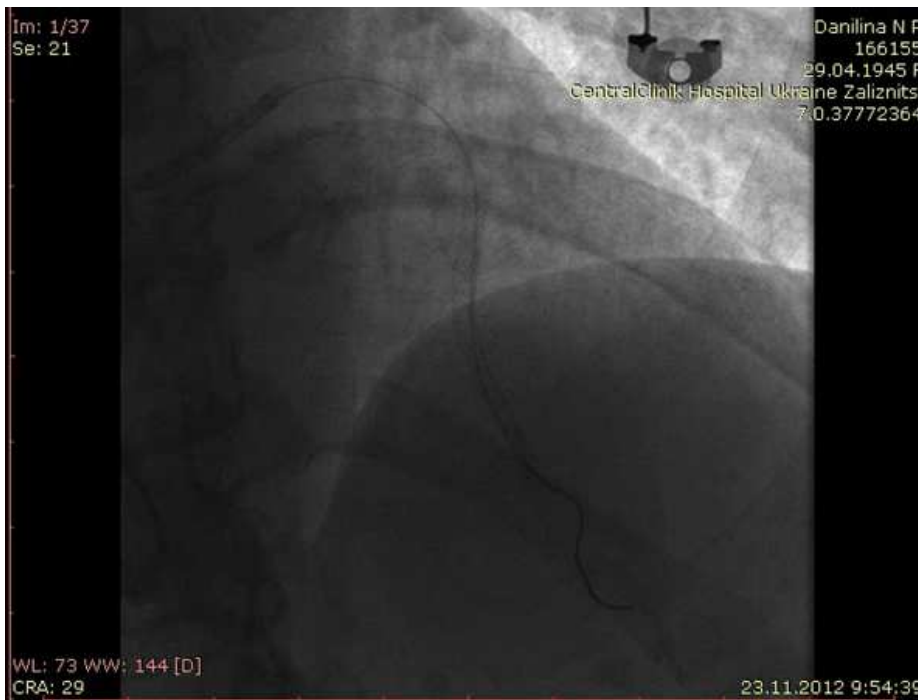

Fig. 4C. Stage of stenting

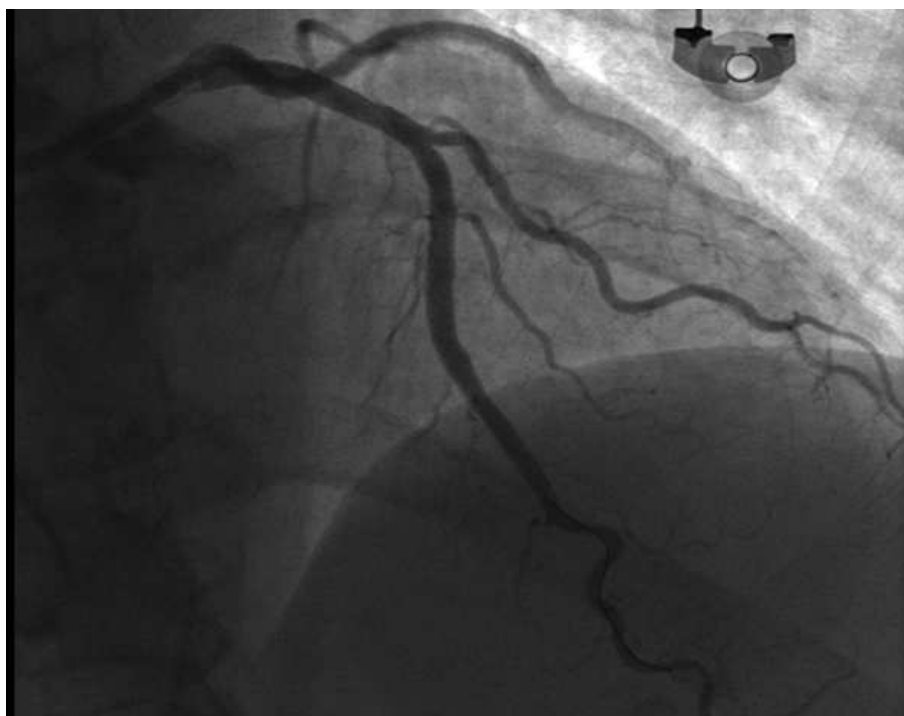

Fig. 5. After stenting (systole)

RECOMMENDATIONS

- Ramipril 5 mg, bisoprolol 5 mg
- Rosuvastatin 40 mg
- Plavix 75 mg
- Aspirin 100mg
- Repeat test with physical exertion after 3 months.

FOLLOW-UP IN 3 MONTH AFTER STENTING

Complaints: none.

Data of the second treadmill test: the test was conducted by Bruce protocol (Fig. 6–7). The test was negative (there was no any ischemic dynamic of the ST segment). Tolerance to physical activity was 10,1 METs. Maximum BP was 160/80 mm Hg.

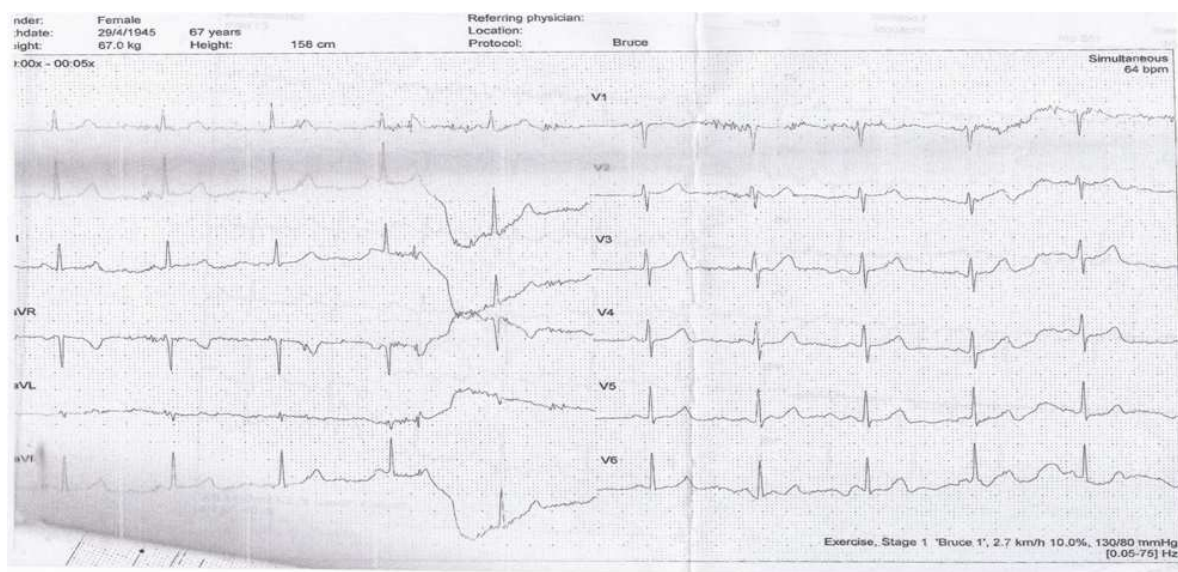


Fig. 6. Early stage.

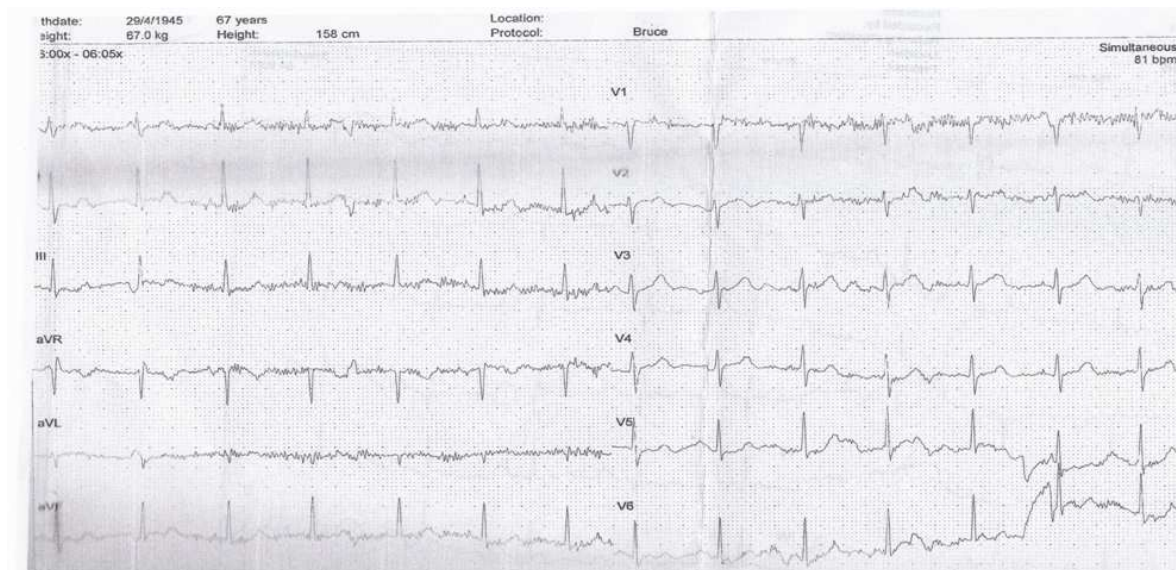


Fig.7. Stage of 10,1 METs.

CONCLUSIONS

The presented clinical case shows that MB should be taken into account in differential diagnosis in patients with symptoms of angina pectoris. Before coronary angiography was conducted (in presented patient), MB was hidden behind the typical for angina pectoris symptoms (including positive results during

stress test). In addition, coronary angiography shown the localization and hemodynamic significance of the myocardial «bridge» and changed the treatment tactic from drug therapy to the stenting. The negative treadmill test and no clinical manifestations of angina pectoris after stenting confirm correctness of the chosen treatment strategy.

REFERENCES

1. Bhat A. Clinical and angiographic profile and follow up of myocardial bridges: a study of 21 cases / A. Bhat, J. Tharakan, T. Titus // *Indian Heart J.* – 1999. – No. 51. – p. 503–507.
2. Shimizu H. Myocardial bridging of the left anterior descending coronary artery in acute inferior wall myocardial infarction / H. Shimizu, E. Kachi, M. Taniuchi // *Clin Cardiol.* – 2001. – No. 24. – p. 202–208.
3. Loukas M. The relationship of myocardial bridges to coronary artery dominance in the adult human heart. / M. Loukas, M. Bowers // *J Anat.* – 2006. – No. 209. – p. 43–50.
4. McDaniel M. C. Coronary artery wall shear stress is associated with progression and transformation of atherosclerotic plaque and arterial remodeling in patients with coronary artery disease / M. C. McDaniel, P. Eshthardi, H. Samady // *Circulation.* – 2011. – No. 124. – p. 779–788.
5. Meijs M. F. Relationship between myocardial bridges and reduced coronary atherosclerosis in patients with angina pectoris / M. F. Meijs, A. Rutten // *J Cardiol.* – 2013. – No. 167. – p. 883–888.
6. Lovric Bencic M. Five-year angiographic and clinical follow-up of patients with drug-eluting stent implantation for symptomatic myocardial bridging in absence of coronary atherosclerotic disease. / M. Lovric Bencic, M. Strozzi // *J Invasive Cardiol.* – 2013. - No. 25. – p. 586-592.
7. Chen H. Coronary artery bypass grafting for myocardial bridges of the left anterior descending artery. / H. Chen, L. Xia // *J Card Surg.* – 2012. – No. 27. – p. 405–407.