

## CLINICAL CASE

УДК 616.127-005.8; 616.379-008.64; 616.12-008.3 4. DOI: 10.26565/2617-409X-2020-5-04

### COMPLETE LEFT BUNDLE BRANCH BLOCK AS PREDICTOR OF CARDIOGENIC SHOCK IN PATIENT WITH ACUTE MYOCARDIAL INFARCTION ON THE BACKGROUND OF DIABETES MELLITUS TYPE 2

*Olena Makharynska, Nataliia Bogun, Irina Oktiabrova, Eke Miracle Chiamaka*

Mail for correspondence: nbogun2801@gmail.com

**Summary:** *Cardiogenic shock is the leading cause of death in patients with acute myocardial infarction, with high hospital mortality rates ~80 %. The incidence of cardiogenic shock among myocardial infarction patients is approximately 7 %. Cardiogenic shock patients are found that pre-existing diabetes is associated with an increased risk of cardiogenic shock and it worsens outcomes, with a longer hospital stay. Cardiogenic shock develops approximately twice as often among diabetics as among nondiabetic patients with acute myocardial infarction. Diabetes mellitus and left bundle branch block are predictors of cardiogenic shock complicating acute myocardial infarction. Except for bad prognosis, left bundle branch block can be a marker of a slowly progressing, degenerative, ischemic or non-ischemic cardiac disease, affecting not only the muscle but also the heart conduction system. Immediate diagnosis and management are required. In this article, a clinical case of acute posterior myocardial infarction complicated by complete left bundle branch block and cardiogenic shock in the patient with concomitant diabetes mellitus type 2 is demonstrated. This article emphasizes the priority of referring patients with left bundle branch block to primary percutaneous coronary intervention, usage of more specific ECG criteria for acute coronary syndrome, the role of myocardial infarction biomarker including sensitive assays for cardiac troponins, and bedside echocardiography which may improve diagnostic accuracy and result in timely intervention in such patients. This article also underlines the role of mechanical circulatory support, urgent reperfusion therapy, and strict control of glycemia in the acute phase of myocardial infarction which may contribute to clinical stability of patients with diabetes mellitus and myocardial infarction complicated by cardiogenic shock.*

**Key words:** left bundle branch block, acute myocardial infarction, cardiogenic shock, diabetes mellitus type 2, mechanical circulatory support

#### Information about author

*Olena Makharynska*, MD, PhD, Associate professor of department of Propaedeutics of Internal Medicine and Physical Rehabilitation, V. N. Karazin Kharkiv National University, 6, Svobody Sq., Kharkiv, Ukraine, 61108. o.makharynska@karazin.ua. <https://orcid.org/0000-0001-5326-1587>.

*Nataliia Bogun*, MD, Assistant of department of Propaedeutics of Internal Medicine and Physical Rehabilitation, V. N. Karazin Kharkiv National University, 6, Svobody Sq., Kharkiv, Ukraine, 61108. [nbogun@karazin.ua](mailto:nbogun@karazin.ua). <https://orcid.org/0000-0002-8176-8171>.

*Irina Oktiabrova*, MD, Assistant of department of Propaedeutics of Internal Medicine and Physical Rehabilitation,

V. N. Karazin Kharkiv National University, 6, Svobody Sq., Kharkiv, Ukraine, 61108. [i.oktiabrova@karazin.ua](mailto:i.oktiabrova@karazin.ua). <https://orcid.org/0000-0001-5083-0131>.

*Eke Miracle Chiamaka*, 4th year students (group BA – 401) of School of Medicine V.N. Karazin Kharkiv National University 6, Svobody Sq., Kharkiv, Ukraine, 61022.

Cardio-vascular and endocrine disorders are two the biggest problems in the routine medical practice. On the one hand, cardiogenic shock (CS) is the most common cause of cardiovascular death in patients with acute myocardial infarction (MI) with mortality rate ~80 %. The incidence of cardiogenic shock among MI patients is approximately 7 %, and in the total infarct population, several important risk factors such as previous MI, infarct size, and location have been identified as predictors of cardiogenic shock, but the death from cardiogenic shock complicating MI is a main contributor to the in-hospital mortality of

MI [1]. On the other hand, recent studies suggest that patients with diabetes mellitus are at increased risk of death after MI, but the presence of diabetes among patients with cardiogenic shock, the influence of diabetes on the risk of shock development in acute MI and the survival rate of diabetic patients with cardiogenic shock is less clear [2]. In the large study with 72,765 cardiogenic shock patients were found that pre-existing diabetes was associated with an increased risk of cardiogenic shock (5.8 % vs 5.2 %; adjusted odds ratio [aOR] 1.14) and it worsens outcomes (higher in-hospital mortality (37.9 % vs 36.8 %;

aOR 1.18), with a longer hospital stay (mean±SEM: 11.6±0.16 vs 10.9±0.16 days) [3].

Several studies in randomly sampled populations, sicker patients with hypertension, suspected or existing coronary artery disease, and post-myocardial infarction patients, have evaluated the impact of LBBB (left bundle branch block) on mortality in patients with isolated LBBB, and found the prognosis of LBBB patients is largely related to the type and severity of the underlying heart disease [4]. Left bundle branch block is an independent negative prognostic marker in acute myocardial infarction. A diagnosis of MI is especially difficult in the setting of LBBB because of the characteristic electrocardiography (ECG) changes caused by altered ventricular depolarization [5]. In the majority of MI, LBBB appearance are a result of involving a large portion of the distal conduction system including both fascicles with a discrete lesion just distal to the bundle of His leading to extensive myocardial damage causes LBBB. A new LBBB is caused by MI appeared usually in anterior or anteroseptal MI locations, involving a large myocardial damaged area. Inferior or posterior infarctions may uncommonly result in a new LBBB from involvement of the more proximal portion of the conduction system supplied by the atrioventricular nodal artery. [6]. In the German study LBBB with acute chest pain was observed in a cohort of patients with high morbidity and mortality rates [7]. Except bad prognosis LBBB can be a marker of a slowly progressing, degenerative, ischaemic or non-ischaemic cardiac disease, affecting not only the muscle but also the heart conduction system [4]. In contemporary medical practice in most patients with suspected acute MI, the clinical utility of new or presumably new left bundle branch block (LBBB) as a diagnostic criterion equivalent to ST-segment elevation is not well established. Even with the introduction of modern intensive care units (ICUs), advanced medical treatment, and invasive devices, in-hospital death rates remain high at 40 %-50 %, despite advances in early revascularization and adjunctive pharmacotherapy [8].

Our 72-year-old patient was delivered by ambulance with complaints of general weakness and dyspnea on minimal physical exertion next day after her chest pain appeared. Intensive chest pain bothered patient on 11-dec-2017 at 9pm for

which the patient has consecutively taken 6 tablets of Nitroglycerin. On admission moment patient denies chest pain as complain. In her past medical history remarkable were: diagnosis of Diabetes mellitus type II was established in 1995, patient constantly received treatment with “Lantus” 40 IU/day and Glybenclimide 5 mg/day. She suffers from Arterial hypertension from 1999, with max number 220/1000 mm Hg, controlled by constant antihypertensive treatment with Ca-channel blocker and b- blocker. Retrosternal chest pain first episode was noticed in 2010 and diagnosis of Coronary artery disease: stable angina IV class according to NYHA was established. In 2011 performed coronarography revealed a diffuse atherosclerosis of coronary arteries. Right coronary artery - critical occlusion before bifurcation with stenting (arrow), TIMI -1 (penetration without perfusion) before stenting, in proximal segment – stenosis 70 %, in middle segment – 50 %. Left coronary artery - prolonged atherosclerotic plaque with sub-occlusion in left anterior descending branch, atherosclerosis of diagonal branches, diffuse stenosis of circumference branch – 60%-70%. Percutaneous coronary intervention (PCI) of the left coronary artery in left anterior descending branch and also of the right coronary artery with drug - eluting stents “Endeavor Resolute” was done. No chest pain or physical exertion intolerance after PCI was observed by her cardiologist. Subsequently, symptoms re-appeared elementarily in 2016.

Objective examination of this patient in the emergency department (ED) during hospitalization revealed lethargic passive patient in the severe state, skin and mucosa pale, visualized acrocyanosis and cyanosis of lips. Patient was overweight (body mass index – 32 kg/m<sup>2</sup>). SpO<sub>2</sub> – 75 %. Vital signs were: blood pressure (BP) - 110 / 60 mm/Hg, heart rate (HR) = pulse rate (PR) – 90 bts in min., respiratory rate (RR) – 18 in min. During lung auscultation were found: decreased breath sounds over inferior and lateral parts of lungs, wheezing over both lung fields and rales below both scapular angles. Left border of the relative heart dullness displaced 1.5 cm away from midclavicular line, heart tones during auscultation found rhythmic, muffled. Abdomen of normal size, symmetric, no tenderness, but liver was enlarged +2cm with no tenderness. Also were observed pitting edemas.

ECG of the patient in ED showed: sinus rhythm, HR – 83 bpm, left axis deviation, LBBB (QRS - 0,12s), paired supraventricular extrasystoles in V1, posterior myocardial infarction (ST-segment elevation greater than or equal to 0.1 mV (1 mm)

in leads with a positive QRS complex, and ST depression greater than or equal to 0.1 mV (1 mm) in leads V1 through V3, in leads with a dominant S wave. Negative T in I and aVL, Q wave start of formation).

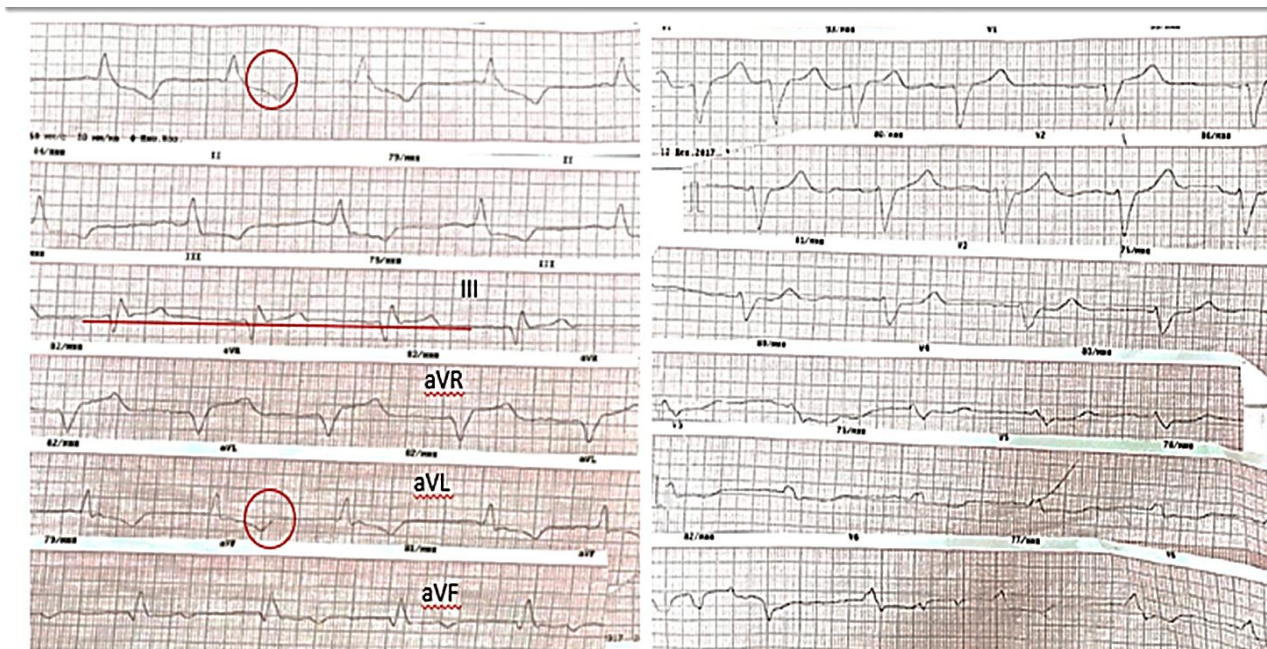


Fig. 1. ECG of our 72 y.old patient during admission in ED

Before patient was referred in ED, previous ECG findings from 2014 were: sinus rhythm, HR 80 in min., normal heart axis. Relative signs of left ventricle (LV) hypertrophy.

Repolarization alternation in anterior-lateral LV wall. Preliminary diagnosis of Acute coronary syndrome (ACS) with ST-elevation was established.

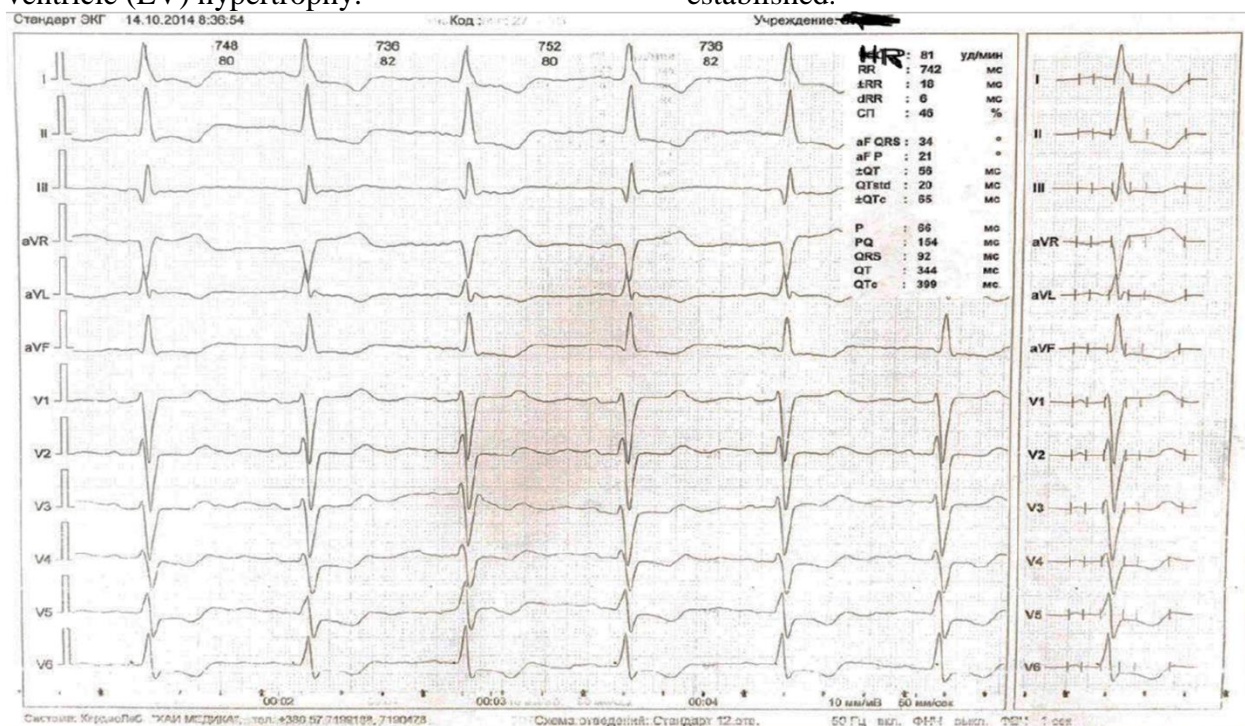


Fig. 2. Previous patient's ECG from 2014 after PCI was performed in 2011



In the complete blood count during admission clinically significant changes were: mild hypochromic anemia (hemoglobin - 80 mg/l (N 120-140 mg/l), red blood cells count - 3,5 (N 3,9-4,7 \* 10<sup>12</sup>), color index - 0,75 (N 0,85 - 1,15)) and leukocytosis 14,7 \* 10<sup>9</sup> (N 4 - 9 \* 10<sup>9</sup>) despite erythrocyte sedimentation rate (EST) remains in normal ranges. Glucose profile was 26,6 (admission) - 15,0 - 13,2 - 10,2 mmol/l on the background of insulin therapy prescribed. Troponin I was elevated till 0,84 ng/ml (N till 0,5). Echocardiographic findings of this patient were represented by dilation of left heart chambers, LV hypertrophy and diffuse contractility decline. LV FDD - 59 mm (N - 35 - 55mm), LV FSD - 48 mm (N - 23 - 38 mm), LV FDV - moderately increased - 174 ml. EF - 35 % (N - 55 - 78 %). Stroke volume - 62 ml - increased Posterior wall thickness in diastole - 13 mm (N - 6 - 13mm). Mild hypertrophy of LV wall. Intraventricular wall thickness in diastole - 12 mm. Mitral regurgitation II stage. Right ventricle parameters were in normal ranges. Left atrium as right one, both, were dilated (45 mm in diameter (N - till 39 mm) and 37 mm in diameter (N - 25-37) respectively).

Despite prescribed according to the current guideline's treatment and previous continuous therapy both Arterial hypertension and Diabetes mellitus with routine dual therapy with aspirin + ticagrelor after PCI was performed deterioration of our patient state continued to develop. After 2 hours from admission, dyspnea, exacerbated by horizontal position and in minimal exertion appeared, RR - 26 in min.

Acrocyanosis and cyanosis of lips remain present. SpO<sub>2</sub> - 82 %. Crackles in lower lung fields during auscultation noticed by ICU department physician. Heart sounds are muffled, rhythmic. HR- 68 bpm. BP- 90/60 mm/Hg on dopamine infusion. Diuresis by catheter 8 - 10:00 is 10 ml. On ECG was seen progression of acute MI on the background of developing cardiogenic shock: sinus rhythm, HR-84 bpm. Left axis deviation. LBBB (QRS - 0,12s). Positive Q wave, posterior myocardial infarction (ST-segment elevation greater than or equal to 0.1 mV (1 mm) in leads with a positive QRS complex in III and aVF, and ST depression greater than or equal to 0.1 mV (1 mm) in leads V1 through V3, ie, leads with a dominant S wave. Reciprocal negative T in I and aVL, Q=0.02 sec, 4mm), negative dynamics comparing with previous. Chest X-ray data showed congestive changes, probable pulmonary edema.

In 3,5 hours from admission clinically deterioration of the patient's state was represented by signs of cardiogenic shock complicated by pulmonary edema. BR became 30 in min. SO<sub>2</sub> continue to decrease - 63 %. HR=Ps=66 in min. BP 85/60 mm Hg on dopamine infusion background. Pitting edemas. Diuresis by catheter 8-14:00 is 20 ml. On behalf of pulmonary edema treatment was added Sol. Morphini hydrochloride 1 % - 1ml in 10 ml 0,9 % NaCl solution bolus, Furosemide 60 mg intravenously, venous tourniquets placement, O<sub>2</sub> inhalation.

Continues therapy didn't show any positive response in patient's state

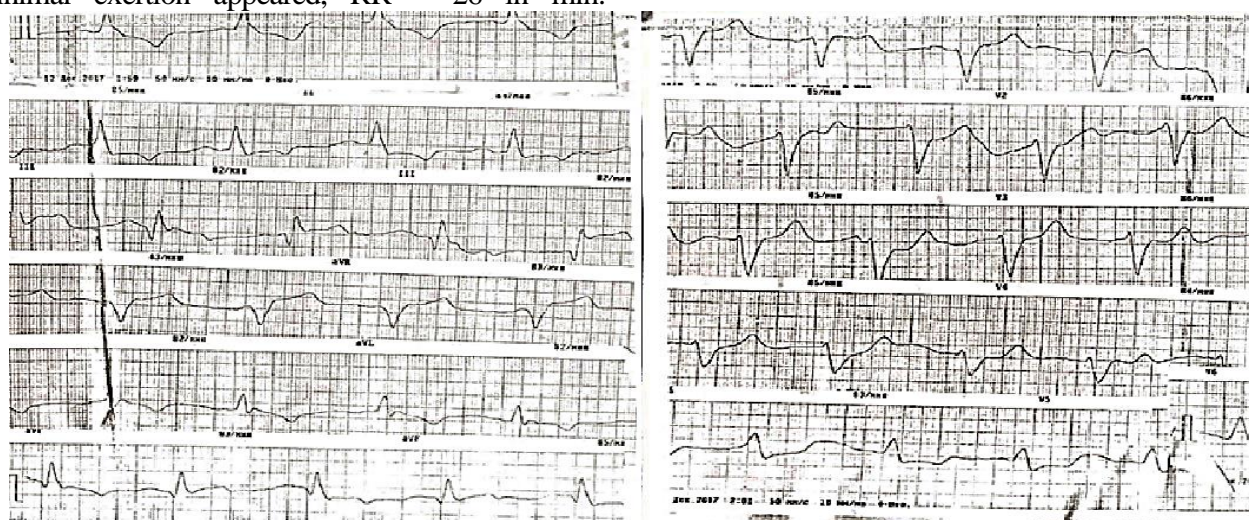


Fig. 3. Acute posterior myocardial infarction progression on ECG 2,5 hours after admission. Positive Q wave, posterior myocardial infarction (ST-segment elevation greater than or equal to 0.1 mV (1 mm) in leads with a positive QRS complex in III and aVF

In 16 hours after admission patient become unconsciousness, pupils were wide, no respiration observed, no BP or pulse on main

vessels found. On ECG: idioventricular rhythm seen (Fig. 4.).

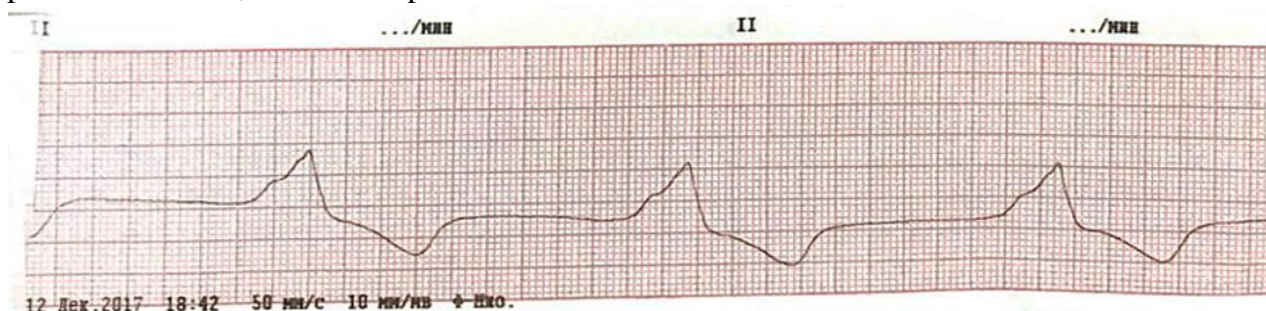


Fig. 4. Idioventricular rhythm in patient with ACS with ST-elevation

Therapy with cardiovascular resuscitation performance, artificial lung ventilation in CMV regimen, on the background of adrenalin 0,18 % – 1 ml and atropine 0,9 % – 10 ml injections weren't successful. Patient remained being unconsciousness with wide pupils and no photoreactions. Respiration was absent, no BP or pulse on main vessels observed. On ECG was seen isoline. Biological death was established.

Final diagnosis was made: CAD: Acute (10. dec. 2017) posterior MI type I, atherosclerotic cardiosclerosis, aorta and coronary arteries atherosclerosis. Stenosing coronary sclerosis (PCI 2011). Arterial hypertension III stage, very high risk. Complicated by acute heart failure IV stage by Killip. Pulmonary edema, recurrent. Cardiogenic shock (12 dec 2017) III stage. Bilateral pleural effusion. Complete left bundle branch block. Asystole (12.12.2017 18:55). Concomitant diseases: Diabetes mellitus 2 type, insulin dependent, severe. Anemia of chronic disease, mild.

Among high mortality rate factors of cardiogenic shock in patients with MI modern scientists define right and left bundle branch block (an independent negative prognostic marker in acute Myocardial infarction (AMI) (30 % vs. 19 %,  $p = 0.012$ , OR 1.57)), advanced age (75 years and more), large myocardial involvement, severe left ventricular dysfunction, severity of end-organ injury. The glucose level at admission is a strong independent predictor for mortality also as a present co-morbidity: STEMI, Dyslipidemia, Stroke or Diabetes mellitus. Our patient according to this list had enormously high risk of death from MI despite continuous medical therapy of her medical problems including PCI

performed. She had 7 among 11 mortality factors present.

### Conclusion

Despite the present scientific data clearly shows approximately two-fold increased risk of cardiogenic shock for diabetic MI patients compared to nondiabetic patients, if shock has developed, outcomes and survival is similar in both groups. Probable causes of MI after PCI performance in DM patients are: re-stenosis after PCI, progression of a separate untreated plaques, or the development of new ones with acceleration of negative remodeling owing to neointimal proliferation after PCI and increased platelet aggregation, small distal vessels microangiopathy and reduced collateral blood flow. The current management of patients with acute myocardial infarction complicated by cardiogenic shock is associated with a high rate of mortality, despite widespread regional implementation of rapid transfer to percutaneous coronary intervention-capable centers for prompt infarct-related artery reperfusion. In all patients with cardiogenic shock after MI in the TRACE registry received ACS noninvasive treatment results were associated with a poor short and long-term outcome of cardiogenic shock after MI [1]. In selected patients as our patient is who was hemodynamically unstable, there might be a benefit associated with early institution of mechanical circulatory support before revascularization. Unloading the left ventricle during MI to decrease LV wall stress, stroke work, and myocardial oxygen demand might limit myocardial cellular loss and decrease the extent of infarction. The major clinical utility of short-term mechanical circulatory support is the reversal of shock by the restoration of cardiac output for

distal organ and coronary perfusion. Even, if in the presence of LBBB, the ECG diagnosis of AMI is not obvious but concordant ST-segment elevation findings (i.e. in leads with positive QRS deflections) appear to be one of the best indicators of ongoing MI with an occluded infarct artery [9]. Otherwise Sgarbossa criteria included ST-segment elevation  $\geq 1$ mm concordant with the QRS complex in any lead, ST-segment depression  $\geq 1$ mm in lead V1, V2, or V3, and ST-segment elevation  $\geq 5$ mm discordant with the QRS complex in any lead may help to establish diagnosis of ACS in patients with positive cardiac troponins despite some concerns over a lack of sensitivity [6]. New diagnostic strategies are needed to be developed with selection of appropriate patients with suspected AMI and LBBB for urgent reperfusion therapy or taking advantages from short-term mechanical circulatory support utilization to prevent further complications and to decrease mortality among this patient. Potential solutions include transportation of patients with LBBB to primary PCI centers before diagnosis ACS was established, usage of more specific ECG criteria for ACS in such patients, increasing of cardiac biomarkers usage or developing of new MI biomarker including sensitive assays for cardiac troponins, and bedside echocardiography to improve diagnostic accuracy and timely intervention [10]. Managing of hyperglycemia in acute phase of MI (i.e. maintain a blood glucose concentration  $\leq 11.0$ mmol/L or 200 mg/dL [9]) with life-important necessary hypoglycemia avoidance may help in maintaining clinical stability of DM patients with MI complicated by cardiogenic shock.

## References

1. Lindholm, M. G., Boesgaard, S., Torp-Pedersen, C., et al. (2005). Diabetes mellitus and cardiogenic shock in acute myocardial infarction. *The European Journal of Heart Failure*, 7, 834 – 839. DOI: 10.1016/j.ejheart.2004.09.007
2. Gustafsson, I., Hildebrandt, P., Seibaek, M., et al. (2000). Long-term prognosis of diabetic patients with myocardial infarction: relation to antidiabetic treatment regimen. *European heart journal*, 21 (23), 1937 – 43. DOI: 10.1053/euhj.2000.2244
3. Echouffo-Tcheugui, J.B., Kolte, D., Khera, S., et al. (2018). Diabetes Mellitus and Cardiogenic Shock Complicating Acute Myocardial Infarction. *The American journal of medicine*, 131 (7), 778-786. DOI: 10.1016/j.amjmed.2018.03.004
4. Etienne Huvelle, I., Renaud Fay, Francois Alla, et al. (2010). Left bundle branch block and mortality in patients with acute heart failure syndrome: a substudy of the EFICA cohort. *European Journal of Heart Failure*, 12, 156–163. DOI: 10.1093/eurjhf/hfp180
5. American Diabetes Association. (2020). Standards of Medical Care in Diabetes — 2020 Abridged for Primary Care Providers. *Clinical Diabetes*, Jan 38 (1), 10-38. DOI: 10.2337/cd20-as01
6. Neeland, I. J., Kontos, M. C., Lemos, J. A. (2012). Evolving considerations in the management of patients with left bundle branch block and suspected myocardial infarction. *Journal of the American College of Cardiology*. 60 (2), 96-105. DOI: 10.1016/j.jacc.2012.02.054
7. Wegmann, C., Pfister, R., Scholz, S., et al. (2015). Diagnostic value of left bundle branch block in patients with acute myocardial infarction. A prospective analysis. *Herz*. 40(8), 1107-14. DOI: 10.1007/s00059-015-4326-z
8. Holger, T., Ohman, E. M., Desch, S., et al. (2015). Management of cardiogenic shock. *European Heart Journal*, 36 (20), 1223–1230. DOI: 10.1093/eurheartj/ehz363
9. Ibanez, B., James, S., Agewall, S., et al. (2018). 2017 Guidelines for the management of acute myocardial infarction in patients presenting with ST-segment elevation: The Task Force for the management of acute myocardial infarction in patients presenting with ST-segment elevation of the European Society of Cardiology (ESC). *European Heart Journal*, 39 (2), 119–177. DOI: 10.1093/eurheartj/ehx393
10. Khan, M. S., Siddiqi, T. J., Usman, M. S., et al. (2019). Intervention in patients with acute myocardial infarction and cardiogenic shock meta-analysis. *The American journal of cardiology*, 123 (2), 218-226.

## ПОВНА БЛОКАДА ЛІВОЇ ГЛІКИ ПУЧКА ГІСА ЯК ПЕРЕДВІСНИК КАРДІОГЕННОГО ШОКУ У ХВОРИХ НА ГОСТРИЙ ІНФАРКТ МІОКАРДУ НА ФОНІ ЦУКРОВОГО ДІАБЕТУ 2 ТИПУ

Махаринська О. С., Богун Н. Ю., Октябрєва І. І., Еке М. Чіамака

Пошта для листування: nbogun@karazin.ua

**Резюме:** Кардіогенний шок є основною причиною смерті у пацієнтів з гострим інфарктом міокарда з високим рівнем госпітальної смертності ~80%. Частота кардіогенного шоку серед хворих на інфаркт міокарда становить приблизно 7%. У пацієнтів з кардіогенним шоком виявлено, що наявний цукровий діабет пов'язаний з підвищеним ризиком кардіогенного шоку і погіршує наслідки з більш тривалим перебуванням у лікарні. Кардіогенний шок розвивається приблизно вдвічі частіше серед діабетиків, ніж серед недіабетичних хворих з гострим інфарктом міокарда. Цукровий



діабет і блокада лівої гілки пучка Гіса є передвісниками кардіогенного шоку, що ускладнює гострий інфаркт міокарда. За винятком поганого прогнозу, блокада лівої гілки пучка Гіса може бути маркером повільно прогресуючої, дегенеративної, ішемічної або неішемічної хвороби серця, вражаючи не тільки міокард, але і провідну систему серця. Потрібна негайна діагностика та лікування. У цій статті продемонстровано клінічний випадок гострого заднього інфаркту міокарда, ускладненого повною блокадою лівої гілки пучка Гіса та кардіогенним шоком у пацієнта із супутнім цукровим діабетом 2 типу. Ця стаття наголошує на пріоритетності спрямування пацієнтів із блокадою лівої гілки пучка Гіса до первинних центрів черезшкірного коронарного шунтування, використання більш конкретних критеріїв ЕКГ для гострого коронарного синдрому, ролі біомаркерів інфаркту міокарда, включаючи чутливі аналізи на серцеві тропоніни, та приліжкової ехокардіографії, що може покращити діагностичну точність та результат своєчасного втручання у таких пацієнтів. Ця стаття також підкреслює роль механічної циркуляторної підтримки, термінової реперфузійної терапії та суворого контролю глікемії в гострій фазі інфаркту міокарда, що може сприяти клінічній стабільності пацієнтів із цукровим діабетом та інфарктом міокарда, ускладненим кардіогенним шоком.

**Ключові слова:** блокада лівої гілки пучка Гіса, гострий інфаркт міокарда, кардіогенний шок, цукровий діабет 2 типу, механічна циркуляторна підтримка

#### Інформація про авторів

*Махаринська Олена Сергіївна*, кафедри внутрішньої медицини і фізичної університету імені В. Н. Каразіна, майдан к. мед. н., доцент кафедри внутрішньої реабілітації Харківського національного Свободи, 6, Харків, Україна, 61108. [i.oktiabrova@karazin.ua](mailto:i.oktiabrova@karazin.ua)  
Харківського національного університету Свободи, 6, Харків, Україна, 61108. <https://orcid.org/0000-0001-5083-0131>.  
імені В. Н. Каразіна, майдан Свободи, 6, [nbogun@karazin.ua](mailto:nbogun@karazin.ua).  
Харків, Україна, 61108 <https://orcid.org/0000-0002-8176-8171>.  
*Октябрєва Ірина Іванівна*, асистент національного університету імені В. Н. Каразіна, майдан Свободи, 6, Харків, Україна, 61022, англомовного навчання, група 401.

## ПОЛНАЯ БЛОКАДА ЛЕВОЙ НОЖКИ ПУЧКА ГИСА КАК ПРЕДИКТОР КАРДИОГЕННОГО ШОКА У ПАЦИЕНТА С ОСТРЫМ ИНФАРКТОМ МИОКАРДА НА ФОНЕ САХАРНОГО ДИАБЕТА 2 ТИПА

*Махаринская Е. С., Богун Н. Ю., Октябрева И. И., Эке Чиамака*

Пошта для листування: [nbogun@karazin.ua](mailto:nbogun@karazin.ua)

**Резюме.** Кардиогенный шок является основной причиной смерти у пациентов с острым инфарктом миокарда, с высокими показателями госпитальной смертности ~80 %. Частота возникновения кардиогенного шока среди пациентов с инфарктом миокарда составляет примерно 7 %. У пациентов с кардиогенным шоком обнаруживается, что ранее существовавший сахарный диабет связан с повышенным риском кардиогенного шока и ухудшает исходы с более длительным пребыванием в стационаре. Кардиогенный шок развивается примерно в два раза чаще у диабетиков, чем у недиабетических пациентов с острым инфарктом миокарда. Сахарный диабет и блокада левой ножки пучка Гиса являются предикторами кардиогенного шока, осложняющие острый инфаркт миокарда. За исключением плохого прогноза, блокада левой ножки пучка Гиса может быть маркером медленно прогрессирующего, дегенеративного, ишемического или неишемического заболевания сердца, поражающего не только миокард, но и проводящую систему сердца. Требуется немедленная диагностика и лечение. В этой статье подчеркивается приоритетность направления пациентов с блокадой левой ножки пучка Гиса к первичным центрам чрескожного коронарного вмешательства, использование более специфических критериев ЭКГ для острого коронарного синдрома, роль биомаркеров инфаркта миокарда, включая чувствительные анализы на сердечные тропонины, и прикроватную эхокардиографию, которая может улучшить диагностическую точность и результат своевременного вмешательства у таких пациентов. В этой статье также подчеркивается роль механической поддержки кровообращения, неотложной реперфузионной терапии и строгого контроля гликемии в острой фазе инфаркта миокарда, что может способствовать клинической стабильности пациентов с сахарным диабетом и инфарктом миокарда, осложненным кардиогенным шоком.

**Ключевые слова:** блокада левой ножки пучка Гиса, острый инфаркт миокарда, кардиогенный шок, сахарный диабет 2 типа, механическая циркуляторная поддержка

**Информация об авторах**

*Махаринская Елена Сергеевна*, к. мед. н., доцент кафедры пропедевтики внутренней медицины и физической реабилитации Харьковского национального университета имени В. Н. Каразина, пл. Свободы, 6 Харьков, Украина, 61108.

[o.makharynska@karazin.ua](mailto:o.makharynska@karazin.ua)

<https://orcid.org/0000-0001-5326-1587>.

*Богун Наталья Юрьевна*, ассистент кафедры пропедевтики внутренней

медицины и физической реабилитации Харьковского национального университета имени В. Н. Каразина, пл. Свободы, 6 Харьков, Украина, 61108  
[nbogun@karazin.ua](mailto:nbogun@karazin.ua)  
<https://orcid.org/0000-0002-8176-8171>.

*Октябрева Ирина Ивановна*, ассистент кафедры пропедевтики внутренней медицины и физической реабилитации Харьковского национального университета имени

В. Н. Каразина, пл. Свободы, 6, Харьков, Украина, 61108.

[i.oktiabrova@karazin.ua](mailto:i.oktiabrova@karazin.ua).

<https://orcid.org/0000-0001-5083-0131>

*Эке Миракл Чиамака*, студентка 4 курса медицинского факультета Харьковского национального университета имени В. Н. Каразина, 61022, Харьков, пл. Свободы, 6  
англоязычная форма обучения, группа 401.

**Conflicts of interest:** author has no conflict of interest to declare.

**Конфлікт інтересів:** відсутній.

**Конфликт интересов:** отсутствует